

# EXCESSIVE UTERINE HAEMORRHAGE — A HISTOPATHOLOGICAL STUDY

Sanallah Gazozai<sup>1</sup> Qurban Ali Bugti<sup>2</sup> Ayesha Siddiq<sup>2</sup> and Naila Ehsan<sup>3</sup>  
Department of Pathology<sup>1</sup>, Radiology<sup>2</sup> and Gynaecology<sup>3</sup>, Bolan Medical College, Quetta

## ABSTRACT

The Histopathological changes of 100 Endometrial curetting and 100 uteri in patients of excessive uterine bleeding in our population at Sandeman Provincial Hospital Quetta were studied. Chronic Endometritis (7%) and the cystic Hyperplasia (9%) were the most important causes of excessive uterine bleeding in endometrial curetting. The patients with abnormal uterine bleeding were mostly post menopausal. No case of endometrial carcinoma was diagnosed in this series. The Histological study of hysterectomy specimen revealed multiple leiomyomas (67%) and adenomyosis (17%) as the commonest causes of uterine bleeding. Three cases of leiomyosarcoma were diagnosed suggesting a lower frequency of uterine malignancy in our country.

## INTRODUCTION

There are many conditions which may lead to abnormal excessive bleeding that occur at regular or irregular intervals in excessive or scant amount especially when prolonged. Some of these cases are the result of identifiable causes like systemic diseases including psychological upsets, endocrine disorders and early pregnancy states. Other conditions including errors in uterine development, infections, endometriosis and uterine neoplasms, like polyps, leiomyomas, and malignant tumors.<sup>2-4</sup>

Uterine bleeding has also been associated with obscure causes like chronic symmetrical enlargement and idiopathic developmental hypertrophy of uterus etc.<sup>5</sup>

The uterine bleeding which is not associated with any organic cause in women of child bearing age belongs to a category known as dysfunctional uterine bleeding.<sup>5</sup> The examination of specimen obtained on dilatation and curettage or endometrial biopsy is a continuous source of frustration for the histopathologist.<sup>1</sup> In these cases a thorough clinical history, detailed physical examination and a correctly timed endometrial biopsy reveals conditions like irregular shedding, anovulatory cycle, inadequate proliferative phase and luteal phase insufficiency (inadequate secretory phase) etc.<sup>1-5</sup>

This histological study was carried out to ascertain the cause of excessive uterine bleeding in our population at Sandeman Provincial Hospital Quetta in the uterine biopsy material and hysterectomy specimen.

## MATERIAL AND METHODS

This study was carried out in the departments of Pathology and Gynaecology and obstetrics of

Bolan Medical College, at Sandeman Provisional Hospital Quetta.

**Patients:** This study included 200 patients of excessive uterine bleeding irrespective of age and parity. In these patients a detailed history was taken and other systemic causes of uterine bleeding like psychological upsets and early pregnancy states were excluded.

A thorough physical examination was also carried out in each patient to exclude physical abnormalities.

**Methods:** The endometrial biopsy material in these patients of excessive uterine bleeding was immediately fixed in 10% formalin. The tissue was processed routinely and 3-4 um thick sections were prepared from paraffin embedded tissue. These sections were stained with haematoxylin and eosin. The slides were then studied carefully to elicit the cause of abnormal uterine bleeding.

The hysterectomy specimens, after washing to remove the excessive blood, were also fixed in 10% formalin. The uteri were measured in length, lateral and anterior-posterior dimensions. The external examination was carried out to record the abnormalities in shape.

Sections were taken routinely passed, paraffin embedded and stained with haematoxylin and eosin. All the sections were then studied by a group of pathologists.

## RESULTS AND OBSERVATIONS

The results of analysis of endometrial biopsies in the cases of excessive/abnormal uterine bleeding revealed the diagnosis of chronic endometritis in 7% cases only, while cystic hyperplasia was observed in 9% of endometrial curettings. Two cases

revealed adenomatous hyperplasia. No case of uterine malignancy was diagnosed in the uterine curettings in this series. The patients having abnormal uterine bleeding were scattered over all age groups.

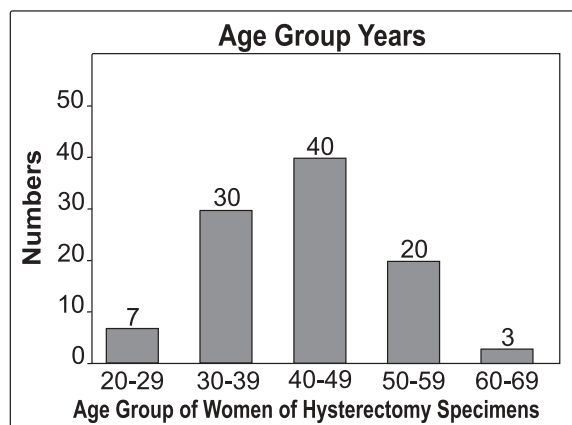
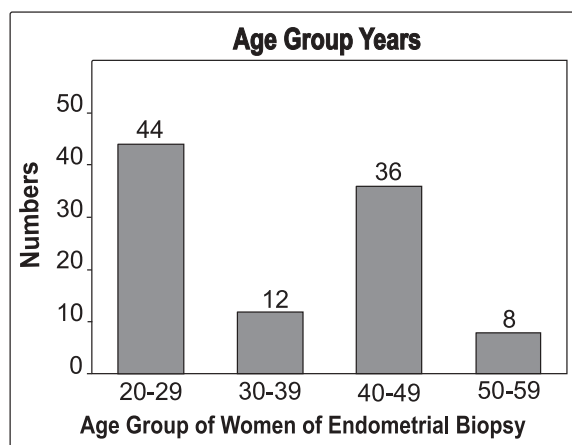
The histological study of the hysterectomy specimens revealed multiple leiomyomas 67% and adenomyosis 17% as the most common causes of excessive uterine bleeding. Some of the uteri did not reveal any cause of bleeding. The other causes of excessive uterine bleeding like cystic Hyperplasia was 6% and leiomyomatous polyps 5%. Eight uteri were distorted with large size. There were 3 cases of leiomyosarcomas and 2 cases of stromal sarcoma. Most of the uteri removed were in the age group of 40-45 years. In this series of hysterectomies 5 were due to leiomyomatous polyps causing bleeding per vaginum.

**Table 1: The Histopathological Pattern of Endometrial Tissue in 100 cases of excessive uterine bleeding.**

Histological Pattern	Number	%
Proliferative Phase	31	31%
Secretory Phase	43	43%
Tuberculous Endometritis	06	06%
Cystic Hyperplasia	09	09%
Adenomatous Hyperplasia	02	02%
Chronic Endometritis	07	07%
Retained products of conception	02	02%

**Table 2: The Histopathological pattern of 100 Uteri removed for menorrhagia.**

Histological Pattern	Number	%
Leiomyoma	67	67%
Adenomyosis	17	17%
Cystic Hyperplasia	06	06%
Leiomyomatous Polyp	05	05%
Leiomyosarcoma	03	03%
Stromal Sarcoma	02	02%



Endometrium with Cystic Hyperplasia

Endometrium Proliferative Phase

## DISCUSSION

The main objective of endometrial curettage in excessive uterine bleeding to exclude the possibility of local intrauterine lesion such as incomplete abortion, uterine polyps, tuberculous endometritis and Carcinoma as a cause of bleeding.<sup>1-2</sup> Our study revealed that all age groups were involved by excessive uterine bleeding, It was found to be more common in our women in twenties and pre-menopausal age groups. These two age groups were involved due to Hormonal disturbances and development of leiomyomas/ adenomyosis which was revealed by the study of hysterectomy specimen in our study. Many women revealed endometrial curettings with normal histology like proliferative/ Secretory phases 43% but chronic endometritis in our study found to be not so common, as compare to other studies 7%, in these women chronic endometritis which is characterized by irregular fibrotic stroma and infiltration of chronic inflammatory cells. The possible cause in our setup may be incomplete abortions which are fairly common and if not properly handled due to lack of adequate medical facilities. The cases of tuberculous endometritis are not so high as in other organs in our setup 6%, glandular cystic hyperplasia was diagnosed in 09% of patients with excessive uterine bleeding on endometrial curettings. Prolonged periods of anovulation with steady estrogen secretion may have a similar effect.<sup>5</sup> Atypical hyperplastic pattern may also occur after prolonged anovulation in the Stein-Leventhal syndrome which regresses after therapeutic induction of ovulation.<sup>4</sup> Most of these patients respond to progesteron or by hysterectomy.<sup>5</sup> The incidence of adenomatous hyperplasia was low in our study 2%.

We did not discover endometrial carcinoma on curettage in our series, which denotes the low

frequency of malignancy in our country. As expected most of the hysterectomy specimen revealed the presence of multiple leiomyomas. 67% which were also associated with adenomyosis 17% in many cases, both submucosal and intramural leiomyomas may lead to excessive uterine haemorrhage.<sup>5</sup> Beside leiomyomas, adenomyosis was found to be a common cause of excessive uterine bleeding 17% in our setup. The adenomyosis may be causing excessive uterine bleeding due to increased uterine size contributed by fibrosis.<sup>5-6</sup> This may lead to symptoms of pain, cramps and abnormal prolonged and profuse menstrual bleeding. In conclusion leiomyomas and adenomyosis are most important causes of excessive uterine bleeding after 3rd decade of life. Fortunately the frequency of uterine malignancy (excluding cervix) including endometrial carcinoma is much low in our setup as compared to western studies.

## REFERENCES

1. Rosai J. (Editor) Ackerman's, Surgical Pathology. St LOUIS: SV Mosby 1989: 1050 – 97.
2. Callenbach-Hellweg G. Editor, Histopathology of the endometrium (English translation by F.D. Dallenbach). New York: springer Verlag 1985.
3. Winkler B, Reumann W, Mitao M, Gallo L, Richar RM. CRum-CP Chlamydial Endometritis: a Histopathological and Immunohistochemical analysis. Am J Surg Path 1984; 8: 771-8.
4. Gore H, Hertig AT. Carcinoma- in-situ of the endometrium. Am J obs Gyn 1966; 94 : 134.
5. Tindall VR, editor. Jeffcoat's principles of gynaecology. London; Butter Worths, 1987: 512-31.
6. Kraus FT. Female genitalia: IN: Kissane. JM Editor, Anderson's Pathology. St. Louis C.V. Mosby 1990; 1725.