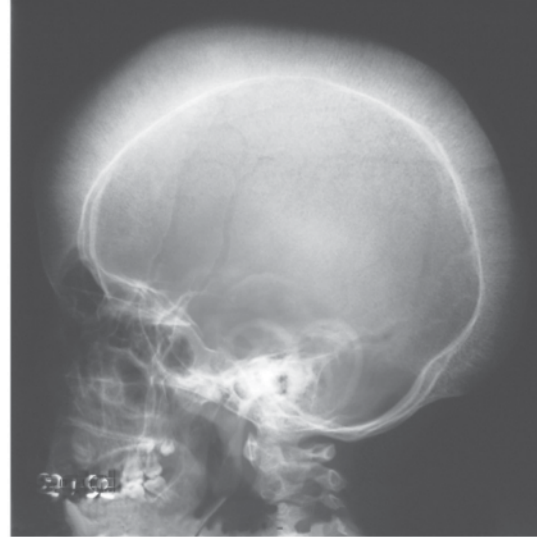
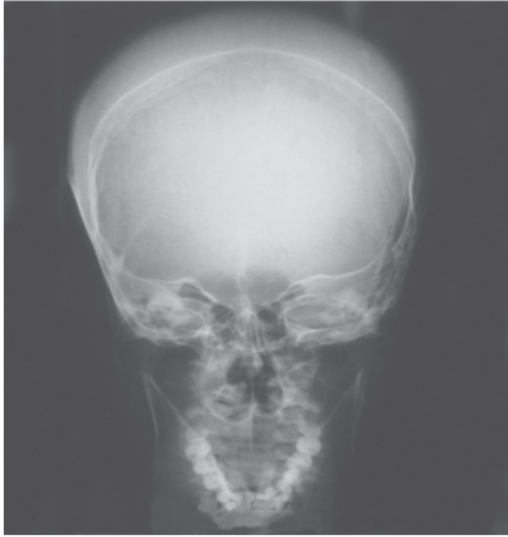


---

## IMAGES IN CLINICAL MEDICINE



Figs. 1 & 2: Skull x-ray film (AP & Lateral view) showing thickening of the outer table with perpendicular striations ... the hairbrush sign.

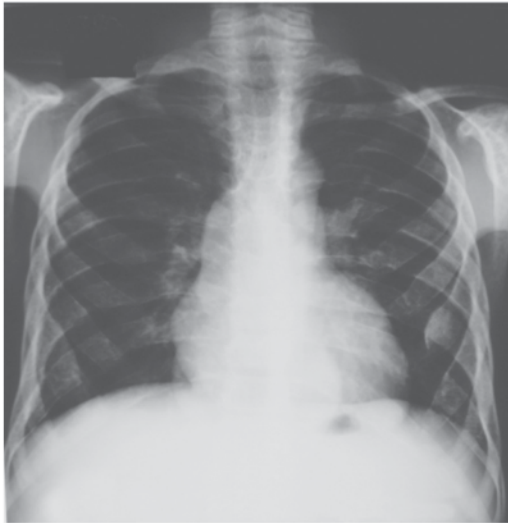

Fig. 3: Gross expansion noted in the ribs due to marrow hyperplasia.

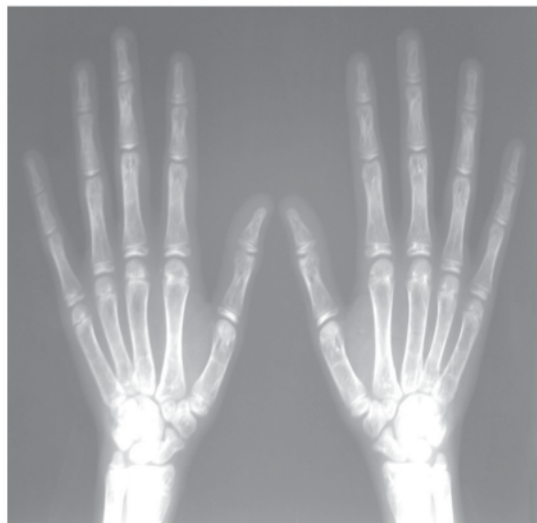

Fig. 4: Gross marrow hyperplasia has expanded and thinned the overlying cortical bone.

### BETA THALASSEMIA MAJOR

Beta thalassemia major is not a rare disorder in communities where literacy rate is low and thus consanguineous marriages a common practice. This boy with beta thalassemia major descended from *Takht-e-Sulaiman* (The Throne of the Prophet Sulaiman - Peace be upon Him) a plateau located in the hills of NWFP province of Pakistan where hemoglobinopathies are not rare.

#### Muhammad Asghar

Associate Professor Radiology  
Gomal Medical College  
D.I.Khan, Pakistan  
Cell No. 03219603124