

# EVALUATION OF USE OF X-RAYS IN NASAL TRAUMA

Khurshid Anwar,<sup>1</sup> Chaudhry Amjad Ali,<sup>1</sup> Junaid Alam,<sup>1</sup> Rabia Sajjad<sup>2</sup>

Department of ENT, <sup>1</sup>CMH Multan, <sup>2</sup>CMH Sargodha, Pakistan

## ABSTRACT

**Background:** The most common site of fracture in face is nasal bones. The objective of the study was to evaluate the use of x-rays of nasal bone in nasal trauma especially in children.

**Material & Methods:** This cross-sectional study was conducted from 2010 to 2012 in ENT Department of Combined Military Hospital, Attock, Pakistan. Patients were recruited via convenience sampling. Sample size was composed of 104 patients of both sexes and all age groups with the history of nasal trauma. All the patients reporting in ENT OPD with x-ray nasal bone advised by other physicians were included. Those advised x-ray nasal bone in this OPD were excluded. Diagnosis of fracture on x-ray nose was made by clinician. Data was collected regarding history of nasal trauma and finding in x-ray. Demographic variables were gender, age and age group. Research variables were presence of fracture on x-ray. All variables were analyzed through SPSS version 16.0.

**Results:** Out of a total of 104 patients 73.07% were male. Mean age was 12 years with a range from 1-27 years. 61.3% of patients were <12 years and x-rays nasal bone was positive only in 18.75% patients out of these. 38.7% of patients were >12 years and x-ray nasal bone was positive in 70% patients out of these. 38.46% patients' x-rays were positive and 61.54% patients x-rays were negative.

**Conclusion:** In the majority of young patients of nasal trauma x-rays nasal bones were negative as compared to adults. Hence it is recommended that x-ray nasal bone should be reserved in those children with nasal deformity, swelling of nose and epistaxis.

**KEY WORD:** Trauma; X-ray; Nasal bones; fracture; Children.

---

**This article may be cited as:** Anwar K, Ali CA, Alam J, Sajjad R. Evaluation of use of x-rays in nasal trauma. Gomal J Med Sci 2017;15:157-60.

---

## INTRODUCTION

The nose is the central and dominant feature of the face and forms an important aesthetic unit.<sup>1</sup> The most common site of fracture in face is nasal bones.<sup>2</sup> In facial trauma, in about 40% cases of facial bone fractures are noted.<sup>3,4</sup> The nasal bones are easily affected to fracture due to its central location, salient position and its low breaking strength.

In adults facial fractures, nasal bones fractures are considered to be more than 50%.<sup>5</sup> Blunt trauma due to road traffic accidents, sports related injury, or physical quarrel are the most common cause of midface injuries and of nasal bone. The natural pro-

trusion and easy breakability of the distal structures in the nose contribute to its inclination for injury.<sup>6</sup> The aesthetic and structural support of central face and airway is because of bones and cartilage of nose, therefore for prevention of nasal deformity and airway compromise, proper evaluation and management is necessary.

With progression of age and nasal bone density, the pattern and extent of the fracture changes as a function of the site direction and severity of the striking force. Nasal fractures are more common in males by a ratio of about 3:1 and have a high incidence in young age of 15-30 years group. Sports injury are the most common cause of nasal fracture. In children nasal fracture is less common in interpersonal altercations and motor vehicle injuries as compared to adults. Children are provided excessive protection against nasal trauma due to certain anatomic and developmental features.

- 1- Lightweight and little size of the child decreases inertial striking force.
- 2- The small amount of hard tissue as compared to soft tissue provides increased skeletal protection.

---

### Corresponding Author:

Dr. Khurshid Anwar  
Consultant ENT Specialist  
CMH Multan  
Multan, Pakistan

E-mail: khurshidanwar62@gmail.com

**Date Submitted:** 06-05-2015

**Date Revised:** 13-03-2017

**Date Accepted:** 27-12-2017

3- In children the developing bones, state of mixed dentition and decreased pneumatization causes increase in elasticity and stability of facial and cranial bones. A less dominant nasal projection absorb and disperse the centrally directed force to adjacent maxilla.<sup>7</sup> The nasal bone is very easily fractured as compared to any other facial bone.<sup>8</sup>

As the diagnosis of nasal bone fracture is mostly clinical therefore imaging is rarely required and is cost restrictive.<sup>9,10</sup> However in case of suspicious naso-orbito-ethmoid fracture computed tomography is necessary to rule out intracranial injuries and peri-orbital injuries. For characterization of septal deflection of the posterior ethmoid computed tomography scans may be helpful.

In hospitals emergency department facial injury may present alone or as part of multiple injuries.<sup>11</sup> Due to prominent position of the nose, it is the most commonly injured part of the face. The most common cause of nasal bone fracture is physical altercations and injuries during sports. In adults, followed by falls and road traffic accidents.<sup>12,13</sup> The highest incidence of facial injuries is associated with boxing.<sup>14</sup> In children the most common cause of nasal fractures is play and sports.<sup>15,16</sup> Nasal fractures may occur alone or in association with other facial injuries. The nasal bones are two and joined in the midline are wedge shaped. The upper portion of the nasal bones is dense and strongly supported by frontal bone and frontal process of maxilla articulation. The lower part of nasal bone is light and wide and easily breakable. Mostly the lower portion of nasal bone is fractured and the upper dense part is rarely fractured.<sup>17</sup> The nasal bone require the least force for fracture as compared to other bone of face. The ratio of male to female is 3:1 in adults,<sup>18-22</sup> and 3:2 in children.<sup>17</sup>

The best view for suspected nasal fracture is lateral view with special nasal techniques. As the treatment of nasal trauma is decided on the basis of clinical finding, x-ray nasal bone is having little importance in evaluation of simple nasal trauma.<sup>23,24</sup> In naso-orbito-ethmoid fracture plain nasal bone x-ray is least reliable and CT scan has to be done for continuous epistaxis or cerebrospinal fluid discharge from nose.

As most nasal fractures do not require any manipulation therefore x-ray nasal bone is unnecessary and cost effective. For simple nasal trauma no x-ray evaluation is necessary but when other facial fractures are suspected CT Scans must be obtained. In trauma patients routine CT scan may demonstrate many unsuspected fractures. The CT scan for nasal bone is fine (2-3mm) axial and coronal section with bone windows and even can demonstrate the extent

of nasal injuries but are rarely needed. These scans must be obtained if nasal fracture is associated with other facial or skull injuries.<sup>25,26</sup>

X-ray evaluation of nasal trauma in a child is even of less value than an adult. This is because the child nose is small and nasal bones are not fused complicate the situation. As most of the injuries occur in the cartilaginous portion which is larger than bony portion and X-ray cannot demonstrate these fractures.

The objective of the study was to evaluate the use of x-rays of nasal bone in nasal trauma especially in children.

**MATERIAL AND METHODS**

This cross-sectional study was conducted from 2010 to 2012 in ENT Department of Combined Military Hospital, Attock, Pakistan. Patients were recruited via convenience sampling. Sample size was composed of 104 patients of both sexes and all age groups with the history of nasal trauma. All the patients reporting in ENT OPD with x-ray nasal bone advised by other physicians were included. Those advised x-ray nasal bone in this OPD were excluded. Diagnosis of fracture on x-ray nose was made by clinician. Data was collected regarding history of nasal trauma and finding in x-ray. Demographic variables were gender, age and age group (<12 & >12 years). Research variables were presence of fracture on x-ray (positive, negative). All variables being categorical except age were analyzed through count and percentages whereas age was calculated as mean and range, using SPSS version 16.0.

**RESULTS**

Out of a total of 104 patients 76 (73.07%) were male and 28 (26.93%) female (Figure 1). Mean age was 12 years with a range from 1 to 27 years. Sixty four (61.5%) patients were <12 years and x-rays nasal bone was positive only in 12 (18.75%) patients out of these. Forty (38.5%) patients were >12 years and x-ray nasal bone was positive in 28 (70%) patients out of these. 40 (38.5%) patients' x-rays were positive and 61.5% patients x-rays were negative (Table 1).

**Table 1: x-rays in below and above 12 years of age patients (n=107)**

Patients	Total no of patients	%	Positive x-ray	%
Below 12 years	64	61.3	12	18.75
Above 12 years	40	38.7	28	70

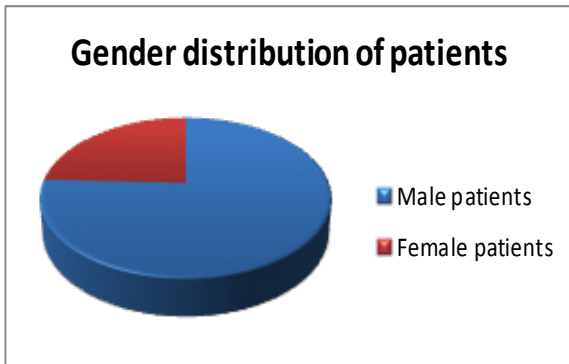


Figure 1: Gender-wise distribution of patients of nasal bone trauma.

## DISCUSSION

The routine x-ray evaluation for simple nasal bone fracture has been criticized by many. The main cause of criticism is a large incidence of false positive and false negative expounding and the lack of its importance in management of these injuries.

In Clayton and Lesser (1986) review 25% of their patient with negative x-ray reports required surgical management. The causes of false negative reports are due to misinterpretation of internasal bone suture, maxillary suture and congenital abnormalities of the nasal bones shows fractures. X-ray of soft tissue lateral view is better in demonstrating fracture of the anterior nasal bone but provide little information about lateral displacement, and it is difficult to differentiate between recent and old fracture on these views. The plain views has least value in these injuries for the evaluation of proper management.

In another study of Mc Arthur the correlation between fracture and the need for surgical management is only 10%. As the management of nasal fractures is largely dependent upon cosmetic and functional effects which are not adequately shown by these x-ray views. There is enough justification for not obtaining x-ray in every case following nasal trauma. But in case of associated suspicion of mid facial injuries series of facial x-rays are required.

## CONCLUSION

In the majority of young patients of nasal trauma x-rays nasal bones were negative as compared to adults. Hence it is recommended that x-ray nasal bone should be reserved in those children with nasal deformity, swelling of nose and epistaxis.

## REFERENCES

1. Fernandes SV. Nasal Fractures: the Taming of the Shrewed. *Laryngoscope* 2004; 114:587-92.
2. Renner GJ. Management of nasal fractures. *Otolaryngol Clin North Am* 1991; 24: 195-213.
3. Bartkiw TP, Pynn BR, Brown DH. Diagnosis and management of nasal fractures. *Int J Trauma Nurs* 1995; 1:11-8.
4. Van As AB, Van Loghen AJ, Biermans BFJ, et al. Causes and distribution of facial fractures in a group of South African children and the value of computed tomography in their assessment. *Int J Oral Maxillofac Surg*, 2006; 35:903-6.
5. Renner G J. Management of nasal fractures. *Otolaryngol Clin North Am*. 1991;24:195-213.
6. Dingman R O, Natvig P. The nose. In: Natvig P, editor. *Surgery of Facial Fractures*. Philadelphia, PA: Saunders 1969; 267
7. Ferreira PC, Amarante JM, Silva PN. Retrospective study of 1251 maxillofacial fractures in children and adolescents. *Plast Reconstr surg* 2005,115:1500-8
8. Rorich RJ, Adams WP. Nasal fracture management: minimizing secondary nasal deformities. *Plast Reconstr Surg* 2000; 106: 266-73.
9. Renner G J. Management of nasal fractures. *Otolaryngol Clin North Am* 1991; 24:195-213.
10. Logan M, O'Driscoll K, Masterson J. The utility of nasal bone radiographs in nasal trauma. *Clin Radiol* 1994;49:192-4
11. Nayyar MS, Ekanayake MBK, Assessment of Maxillofacial injuries. *Pak Oral Dental J* 2001; 21:12-8.
12. Alvi A, Dohesty T, Lewen G. Facial fractures and concomitant injuries in trauma patients. *Laryngoscope* 2003;113:102-6.
13. Murphy Rx, Birmingham KL, Okunski WJ, Wasser T, The influence of air bag and restraining devices on the patterns of facial trauma in motor vehicle collisions. *Plast Reconstructive surg* 2000; 105:516-20.
14. Bledsoe GH, LiG, Levy F. Injury risk in professional boxing. *Southern Med J* 2005: 98:994-8.
15. Kelly P, Crawford M, Hinguera S, Hollier LH. 294 consecutive facial fractures in an urban trauma center: Lessons learned. *Plast Reconstructive surg*, 2005; 116; 42e-9e.
16. Duma SA, Jernigan VV. The effects of airbags on orbital fracture patterns in frontal automobile crashes ophthal *plast Reconstr surg* 2003; 113:102-6.
17. Mondin V, Rinaldo A, Ferlito A. management of nasal bone fractures. *Am J otolaryngol* 2005; 26:181-5.
18. Hussain SS, Ahmad M. Khan MI. Anwar M. Amin M. Ajmal S. et al, Maxillofacial trauma: current practice in management at Pakistan Institute of Medical Sciences Islamabad. *J Ayub Med Coll Abbottabad* 2003;15:8-11.
19. Ambreen A, Shah R. Causes of Maxillofacial injuries a three years study. *J Surg Pak* 2006; 6:25-7.
20. Zakai MA. Islam I. Memon S, Aleem A. Pattern of maxillofacial injuries received at AbbasiShaheed Hospital, KMDC Karachi. *Ann AbbasiShaheed Hospital* 2002;7:291-3.
21. Abbas I. Ali K. Mirza YB. Spectrum of mandibular

- fractures at a tertiary care dental hospital in Lahore. J Ayub Med coll Abbottabad 2003;15:12-4.
22. Khan SU, Khan M, Khan AA, Murtaza B, Maqsood A, Ibrahim W, et al. Etiology and pattern of maxillofacial injuries in the Armed forces of Pakistan. J coll physician surg Pak 2007;17:94-7.
23. Sharp JF, Denholm S. Routine x-rays in nasal trauma. The influence of audion clinical practice. JR soc Med 1994;87:153-4.
24. Logan M, O Driscoll K, Masterson J. The utility of nasal bone radiographs in nasal trauma. Clin radial 1994;49:192-4.
25. Rodt T, Bartling SO, Zajaczek JE, Vafa MA, Kapa-pa T, Majdani O, et al. Evaluation of surface and volume rendering in 3D-CT of facial fractures. Dentomaxillofac Radiol 2006;35:227-31.
26. Lee JC, Andrews BT, Abdollahi H, Lambi AG, Pereira CT, Bradley JP. Computed tomography image guidance for more accurate repair of anterior table frontal sinus fractures. J Craniofac Surg 2015;26:64-7.

**CONFLICT OF INTEREST**  
Authors declare no conflict of interest.  
**GRANT SUPPORT AND FINANCIAL DISCLOSURE**  
None declared.

**AUTHORS' CONTRIBUTION**

Conception and Design: KA, CAA  
Data collection, analysis & interpretation: KA, CAA, JA,  
Manuscript writing: KA, RS