

## CASE REPORT

# INTESTINAL MALROTATION IN 35 YEAR OLD WOMEN FROM PESHAWAR, PAKISTAN

Zubair Ahmad Khan<sup>1</sup>, Omer Nasim<sup>1</sup>, Zeinab Hussain<sup>2</sup>, Jamil Ahmad<sup>1</sup>

<sup>1</sup>Department of Surgery, <sup>2</sup>Department of Medical Research, Rehman Medical College, Peshawar, Pakistan

## ABSTRACT

Thirty five years old women presented to the Accident and Emergency Department with acute onset right upper quadrant abdominal pain with normal vitals. CT images revealed a malrotation causing midgut volvulus and intestinal obstruction. On emergency exploratory laparotomy, the gut loops showed partial ischemia due to a double twist at the root of mesentery and malrotation of the gut along with the caecum which was mobile coming from left iliac fossa and lying in the right iliac fossa. Duodeno-jejunal junction was identified. The coils of the intestine were untwisted and rotation was corrected. The gut color changed back to normal. She was discharged painless after routine post-operative care.

**KEY WORDS:** Malrotation; Volvulus; Intestinal Obstruction; Mesentery; Duodenum; Small Intestine.

**This article may be cited as:** Khan ZA, Nasim O, Hussain Z, Ahmad J. Intestinal malrotation in 35 year old women from Peshawar, Pakistan. *Gomal J Med Sci* 2019;17(4):145-9. <https://doi.org/10.46903/gjms/17.04.2097>

## INTRODUCTION

Intestinal malrotation, also called nonrotation or incomplete rotation is any change or variation in the rotation of the gastrointestinal tract during its formation in the embryological stages. It is the complete or partial failure of the rotation of the midgut around the mesenteric vessels during embryogenesis.<sup>1,2</sup>

Estimates show that midgut malrotation occurs in about one in 500 newborns and is presented in neonatal life in up to 64-80% of cases.<sup>3</sup> In 0.2-0.5% cases it may present later in adulthood and it might be asymptomatic for life.<sup>4-6</sup> In adults, malrotation is mostly because of midgut volvulus and obstruction is predominantly seen in the colon.<sup>7</sup> The prevalence rate in men and women is almost equal.<sup>8</sup>

The failure of the normal embryological midgut rotation can lead to a variety of abnormalities. Most frequently small intestine remains on the right lateral side of the abdomen while caecum remains on the

left side due to the absence of ligament of Treitz.<sup>9</sup> The caecum stays connected to the right site of the abdominal wall through Ladd's bands, which are persisting peritoneal fibrous stalks. These bands usually trap the descending duodenum and lead to intermittent gastro-intestinal obstruction. Malfixation is another anomaly in which the intestines themselves are situated correctly, except for a small vertical connection of the small bowel mesentery. This results in limited attachment to the retroperitoneum and makes the small intestine more mobile making it more prone to midgut volvulus.<sup>2,4,10</sup>

Malrotation in adults tends to have an inconsistent obscure clinical presentation with non-specific symptoms, which often leads to a delay in diagnosis. Adult malrotation usually presents with intermittent abdominal pain, weight loss, bloating, nausea, and bile stained vomiting.<sup>11</sup>

## CASE PRESENTATION

Thirty five years old women presented with severe abdominal pain around the umbilicus, radiating to the right hypochondrium and right iliac fossa, starting about five 5 hours ago. There was no history of trauma, weight loss, loss of appetite or change in bowel habits. This was the first time she had felt pain of such intensity with no significant past medical or surgical history. Her BP was 112/60 mmHg, pulse 75/min, oxygen saturation 96% and temp 98.8 F. She was given injection morphine for pain. General physical examination was unremarkable with no anemia or jaundice. She had no co-morbidities.

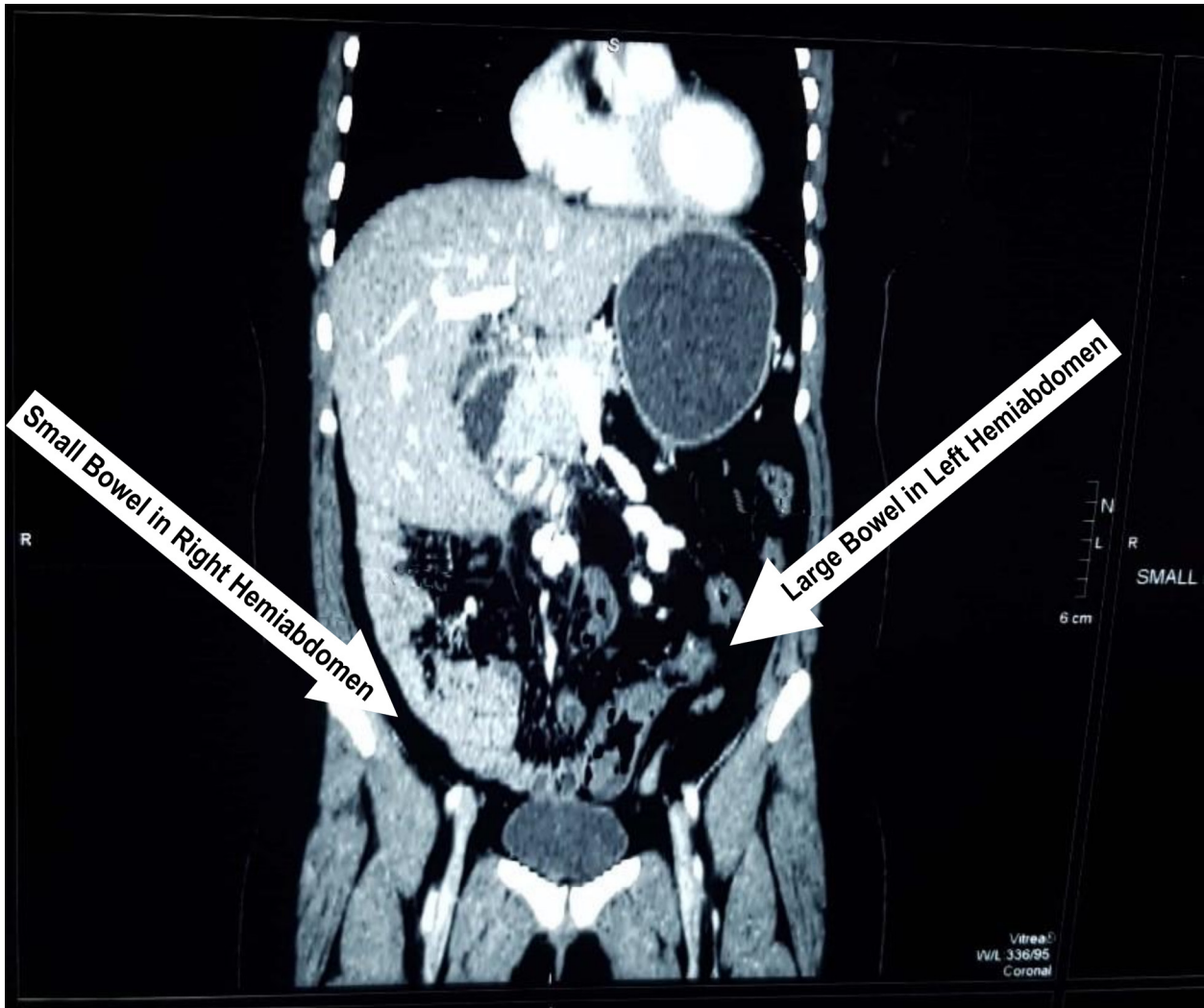
## Corresponding Author:

Dr. Zubair Ahmad Khan  
Associate Professor  
Department of Surgery  
Rehman Medical College, Peshawar  
E-mail: [zubair.ahmad.khan71@gmail.com](mailto:zubair.ahmad.khan71@gmail.com)

**Date Submitted:** 17-09-2019

**Date Revised:** 27-09-2019

**Date Accepted:** 31-09-2019



**Figure 1: Coronal view of CT abdomen showing small bowel in right hemiabdomen and large bowel in left hemiabdomen in 35 years old women with intestinal malrotation.**

Examination of the abdomen revealed tenderness in the right iliac fossa and epigastric region.

Her CBCs, LFTs, RFTs, serum electrolytes, and serum amylase were all within normal ranges. B-hCG showed absence of tubal pregnancy. Abdominal ultrasonography showed distended fluid filled bowel loops, suggestive of obstruction. Conservative management was done.

CT Abdomen with contrast revealed mesenteric volvulus with small bowel in right hemiabdomen and large bowel in left hemiabdomen (Figure 1). A transverse view revealed dilated duodenum and displaced duodeno-jejunal junction, suggestive of obstruction (Figure 2). Whirling of the mesenteric root was also seen which is common in cases of

malrotation (Figure 3).

Emergency laparotomy showed partially ischemic gut loops due to double twist at the root of mesentery. There was malrotation of the gut along with the caecum, which was mobile coming from left iliac fossa and lying in the right iliac fossa. Duodeno-jejunal junction was identified. The coils of the intestine were untwisted, rotation corrected, and the gut color changed back to normal. Appendectomy was performed to avoid any confusion in the future regarding the pain of appendicitis, as the caecum was fixed back into the left iliac fossa. Post-operatively she was put on intravenous antibiotics/ fluids and analgesic. She was discharged as painless on the 3<sup>rd</sup> post-operative day.

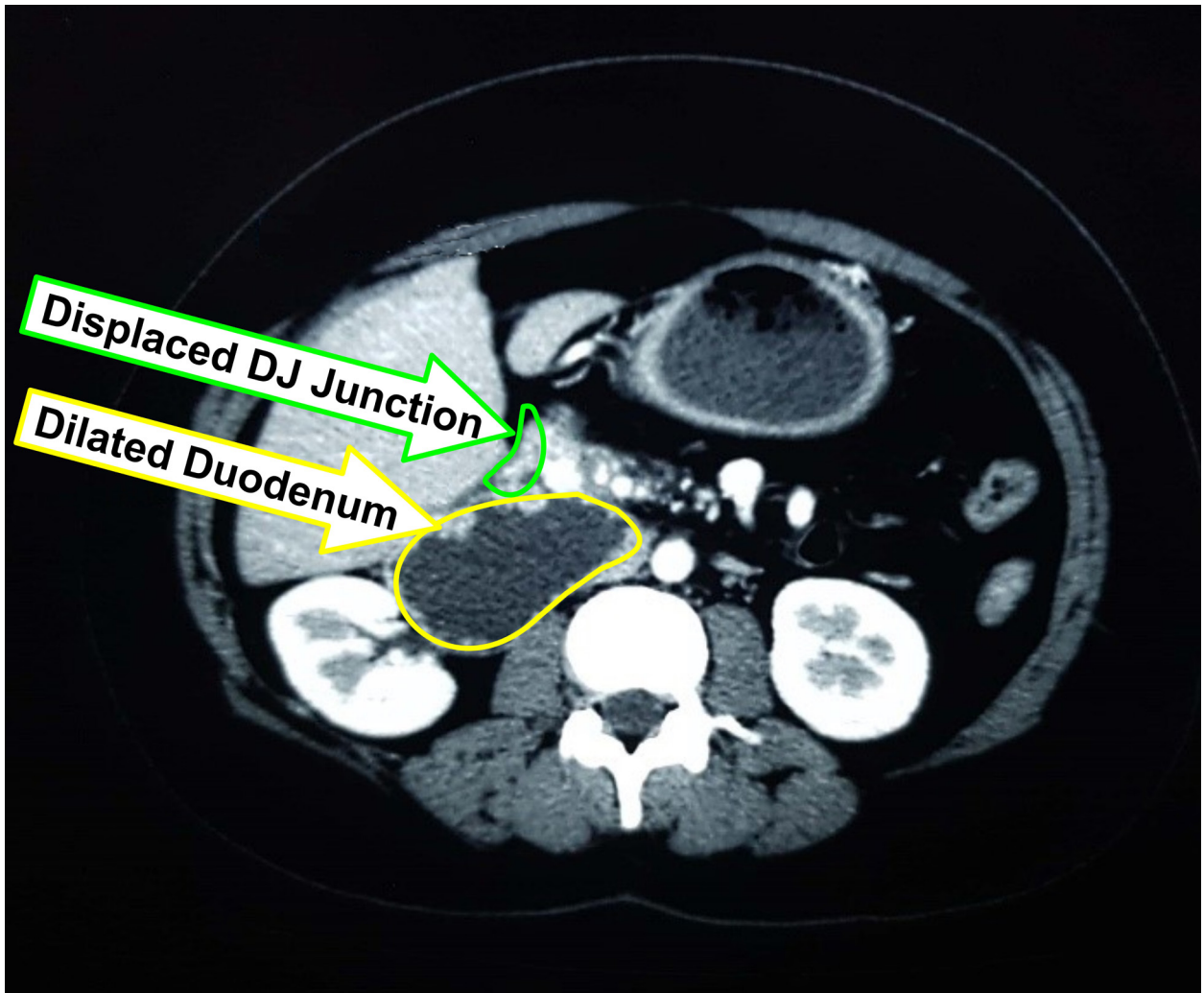


Figure 2: Transverse view of CT-scan abdomen showing dilated duodenum and displaced duodeno-jejunal junction in 35 years old women with intestinal malrotation.

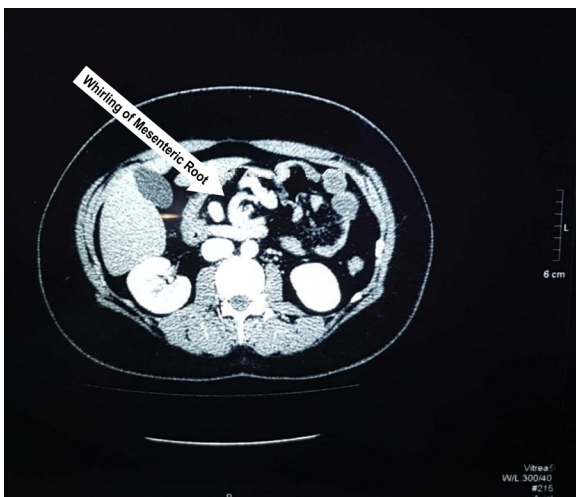

Figure 3: A transverse view of CT abdomen showing whirling of mesenteric root in 35 years old women with intestinal malrotation.

## DISCUSSION

Clinical presentation in adults may be with nausea, vomiting, and recurrent colicky pain, most likely because of chronic partial obstruction.<sup>12-14</sup> It may present with diarrhea due to the presence of a chronic volvulus leading to protein loss<sup>1</sup>, and malabsorption due to not being able to eat. Imaging studies include computerized tomography, plain radiography, ultrasonography, and contrast enhanced stomach-duodenum radiography, with the highest accuracy.<sup>15</sup> One of the uncommon radiological signs is the corkscrew sign, caused by the dilatation of multiple duodenal segments as well as the jejunal folding leading to the relocation of duodeno-jejunal junction.<sup>16</sup> Through ultrasound studies, the superior mesenteric vein (SMV) which lies to the anterior or left of the superior mesenteric artery (SMA) may be visible. Doppler ultrasound may show the whirlpool sign, which is also typical of malrotation.<sup>17</sup> It refers to the rotation



of SMV around the SMA. An additional diagnostic sign is that jejunal arteries are lying to the right side instead of the left side in a CT scan.<sup>18</sup> Elective laparotomy is necessary because malrotation of the gut can lead to acute intestinal obstruction causing gut ischemia.<sup>19</sup> Since 1936, the standard operating procedure of elective treatment of intestinal malrotation has been Ladd's procedure.<sup>20</sup> The steps are to firstly, have the volvulus in the midgut is untwisted; the obstructing bands are divided; segments of the small intestine and colon are set to neutral positions, and an appendectomy is performed to prevent any confusion in the future of diagnosis of appendicitis. Extensive small bowel resection may have to be performed in some patients. However, in these patients subsequent complications could be unpreventable. Alternative procedures used in previous cases in literature include endoscopic untwisting, cecopexy and laparoscopic management.

The diagnosis of asymptomatic intestinal malrotation is unusual, thus it is often not in differential diagnosis.<sup>21</sup> Many adults have chronic symptoms which may have existed for a period longer than six months.<sup>22</sup> Some of the patients may come with insidious acute pain starting within hours and causing severe disability due to severity of the pain. About 15% of patients with malrotation may present with acute volvulus which would have severe abdominal pain, either with or without signs of shock.<sup>5</sup> In the case that presented to us the patient had severe abdominal pain with no chronic symptoms, and was hemodynamically stable.

According to one study, over 90% patients are expected to have a good prognosis after having surgery for small bowel volvulus.<sup>23</sup>

## CONCLUSION

We presented a rare case of intestinal obstruction due to malrotation of the gut leading to volvulus. Given the acute presentation of the patient explained in the case report, timely CT dependent diagnosis and appropriate surgical intervention can always give a good output.

## REFERENCES

- Sahu SK, Raghuvanshi S, Sinha A, Sachan PK. Adult intestinal malrotation presenting as midgut volvulus; case report. *J Surg Arts* 2012; 5(1): 18-21.
- Emanuwa OF, Ayantunde AA, Davies TW. Midgut malrotation first presenting as acute bowel obstruction in adulthood: a case report and literature review. *World J Emerg Surg* 2011 Jul 29; 6(1): 22. <https://doi.org/10.1186/1749-7922-6-22>
- Matzke GM, Moir CR, Dozois EJ. Laparoscopic Ladd procedure for adult malrotation of the midgut with cocoon deformity: report of a case. *J Laparoendosc Adv Surg Tech* 2003 Oct 1; 13(5): 327-9. <https://doi.org/10.1089/109264203769681736>
- Torres AM, Ziegler MM. Malrotation of the intestine. *W J Surg* 1993 May 1; 17(3): 326-31. <https://doi.org/10.1007/BF01658699>
- Fung AT, Konkin DE, Kanji ZS. Malrotation with midgut volvulus in an adult: a case report and review of the literature. *J Surg Case Rep* 2017 May; 2017(5). <https://doi.org/10.1093/jscr/rjx081>
- Low SF, Ngiu CS, Sridharan R, Lee YL. Case Report: Midgut malrotation with congenital peritoneal band: a rare cause of small bowel obstruction in adulthood. *BMJ Case Rep* 2014; 2014. <https://doi.org/10.1136/bcr-2013-202690>
- Bernstein SM, Russ PD. Midgut volvulus: a rare cause of acute abdomen in an adult patient. *AJR. American J Roentgenol* 1998 Sep; 171(3): 639-41. <https://doi.org/10.2214/ajr.171.3.9725289>
- Zengin A, Uçar Bİ, Düzgün ŞA, Bayhan Z, Zeren S, Yaylak F, et al. Adult midgut malrotation presented with acute bowel obstruction and ischemia. *Int J Surg Case Rep* 2016 Jan 1; 22: 5-7. <https://doi.org/10.1016/j.ijscr.2016.03.018>
- Haak BW, Bodewitz ST, Kuijper CF, de Widt-Levert LM. Intestinal malrotation and volvulus in adult life. *Int J Surg Case Rep* 2014 Jan 1; 5(5): 259-61. <https://doi.org/10.1016/j.ijscr.2014.02.013>
- Ladd WE. Surgical diseases of the alimentary tract in infants. *New England J Med* 1936 Oct 15; 215(16): 705-8. <https://doi.org/10.1056/NEJM193610152151604>
- Butterworth WA, Butterworth JW. An adult presentation of midgut volvulus secondary to intestinal malrotation: A case report and literature review. *Int J Surg Case Rep* 2018; 50: 46-9. <https://doi.org/10.1016/j.ijscr.2018.07.007>
- Araújo, Ubirajara Rutilio Mendes e Ferreira de, El Tawil, Imad Izat. Adult intestinal malrotation, case report and literature review. *ABCD: Arq Bras Cir Dig* 2009; 22(4): 240-2. <https://doi.org/10.1590/S0102-67202009000400013>
- Wanjari AK, Deshmukh AJ, Tayde PS, Lonkar Y. Midgut malrotation with chronic abdominal pain. *North Am J Med Sci* 2012 Apr; 4(4): 196-8. <https://doi.org/10.4103/1947-2714.94950>
- Ameh EA, Nmadu PT. Intestinal volvulus: aetiology, morbidity, and mortality in Nigerian children. *Pediatr Surg Int* 2000; 16 (1-2): 50-2. <https://doi.org/10.1007/s003830050013>
- Duran C, Ozturk E, Uraz S, Kocakusak A, Mutlu H, Killi R. Midgut volvulus: value of multidetector computed tomography in diagnosis. *Turk J Gastroenterol* 2008 Sep; 19(3): 189-92.
- Gamblin TC, Stephens Jr RE, Johnson RK, Rothwell M. Adult malrotation: a case report and review of the literature. *Curr Surg* 2003; 60(5): 517-20. [https://doi.org/10.1016/S0149-7944\(03\)00030-8](https://doi.org/10.1016/S0149-7944(03)00030-8)
- Orzech N, Navarro OM, Langer JC. Is ultrasonography a good screening test for intestinal malrotation? *J Pediatr Surg* 2006; 41(5): 1005-9. <https://doi.org/10.1016/j.jpedsurg.2005.12.070>
- Applegate KE, Anderson JM, Klatte EC. Intes-

- tinal malrotation in children: a problem solving approach to the upper gastrointestinal series. Radiographics 2006 Sep-Oct; 26(5): 1485-500. <https://doi.org/10.1148/rg.265055167>
19. Hota PK, Abhishek D, Bhaskar V. Adult midgut malrotation with Ladd's band: a rare case report with review of literatures. Bali Med J 2014; 3(3): 137-42. <https://doi.org/10.15562/bmj.v3i3.91>
  20. Malek MM, Burd RS. The optimal management of malrotation diagnosed after infancy: a decision analysis. Am J Surg 2006; 191(1): 45-51. <https://doi.org/10.1016/j.amjsurg.2005.10.002>
  21. Hsu YC, Hsu LS, Huang WS, Weng JC, Chen CW. Short bowel syndrome caused by laparoscopic loop enterostomy of the jejunum in an adult with undiagnosed intestinal malrotation: A case report. Medicine 2018 Oct; 97(40): e12712. <https://doi.org/10.1097/MD.00000000000012712>
  22. Yanez R, Spitz L. Intestinal malrotation presenting outside the neonatal period. Arch Dis Child 1986; 61(7): 682-5. <https://doi.org/10.1136/adc.61.7.682>
  23. Li X, Zhang J, Li B, Yi D, Zhang C, Sun N, et al. Diagnosis, treatment and prognosis of small bowel volvulus in adults: A monocentric summary of a rare small intestinal obstruction. PloS One 2017 Apr 20; 12(4): e0175866. <https://doi.org/10.1371/journal.pone.0175866>

**CONFLICT OF INTEREST**

Authors declare no conflict of interest.

**GRANT SUPPORT AND FINANCIAL DISCLOSURE**

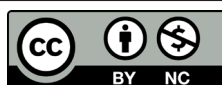None declared.

**AUTHORS' CONTRIBUTION**

The following authors have made substantial contributions to the manuscript as under:

Conception or Design:	ZAK, ON
Acquisition, Analysis or Interpretation of Data:	ZAK, ON, ZH, MS, JA
Manuscript Writing & Approval:	ZAK, ON, ZH, MS, JA

All the authors agree to be accountable for all aspects of the work in ensuring that questions related to the accuracy or integrity of any part of the work are appropriately investigated and resolved.



Copyright © 2019 Zubair Ahmad Khan, et al. This is an Open Access article distributed under the terms of the Creative Commons Attribution-Non Commercial 4.0 International License, which permits unrestricted use, distribution & reproduction in any medium provided that original work is cited properly.