

CASE REPORT

CONGENITAL MALARIA IN A NEONATE

 Kalathil Gopalakrishna Pillai Gopikrishnan^{1,2},  Kalaivanan Naveen Chandher¹,
 Selvakumar Jagadeeswari^{1,2}

¹Department of Paediatrics, Sree Balaji Medical College and Hospital, Chennai, ²Bharath Institute of Higher Education and Research, Chennai, Tamil Nadu, India

ABSTRACT

Congenital malaria isn't common even though malaria is endemic in India. Here, we will be reporting about a neonate of age seven days with splenomegaly and fever diagnosed as congenital malaria. On smear study it was found to have malarial parasite incidentally. In a case of neonatal sepsis congenital malaria can be suspected. Early diagnosis and treatment is thus important in preventing neonatal mortality.

KEY WORDS: Malaria; Sepsis; Neonate; Newborn; Splenomegaly; Fever; Parasites; Mortality; Chloroquine; India.

Cite as: Gopikrishnan KGP, Chandher KN, Jagadeeswari S. Congenital malaria in a neonate [case report]. Gomal J Med Sci 2021 Oct-Dec; 19(4):161-2. <https://doi.org/10.46903/gjms/19.04.1031>

INTRODUCTION

Congenital malaria is defined as demonstration of malarial parasites in the peripheral blood smear study of a neonate from day 1 to day 7 of life. In malarial endemic countries, the maternal antibody levels are high; hence it is rare to see clinically apparent congenital malaria. It is often misdiagnosed as neonatal sepsis as the symptoms are nonspecific.

CASE REPORT

A neonate aged seven days presented with complaints of unable to feed, low grade fever, and loose watery stools for two days. On clinical examination the neonate was found to have a temperature of 101F, pallor + and icterus+. On palpation of abdomen the liver was palpable 3 cm below the RCM and the spleen was palpable 7 cm below the LCM. The respiratory system, cardiovascular system and central nervous system did not reveal any significant findings. The baby was initially diagnosed as neonatal sepsis and was initially started with IV gentamycin and ampicillin. Blood investigations during admission revealed the following; Hb 10 gm/dL, TLC 13000 cells/cumm, with 52% neutrophils, 45% leucocytes & 3% monocytes, platelets 60,500 cells/cumm, total serum bilirubin 10 mg/dL, serum bilirubin indirect 9 mg/dL, serum SGPT 470 IU/L, and CRP 22 mg/dL.

Corresponding Author:

Dr. Kalathil Gopalakrishna Pillai Gopikrishnan
Resident, Department of Paediatrics
Sree Balaji Medical College and Hospital
Chennai, Tamil Nadu, India
E-mail: drkggopikrishnan@gmail.com

Date Submitted: 19-06-2021
Date Revised: 21-08-2021
Date Accepted: 03-09-2021

The culture reports of CSF, urine, blood showed no growth. Chest X-ray did not reveal any abnormalities. The smear study showed *Plasmodium vivax* (trophozoites and schizonts) with 2% parasite index. The baby was started with chloroquine 10 mg/kg dose followed by 5 mg/kg at 6, 24, and 48 hours. Following which the fever reduced and the size of spleen gradually reduced over the period of next seven days. Five days after initiation of therapy the child's parasitemia resolved completely. There was an increase in TLC to 14000 cells/cu mm, platelets saw a rise to 175560 cells per cumm, and CRP reduced to 5.2 mg/dL. The baby was discharged on day five of admission and recovered well on follow-up.

On re-evaluation of the mother, it was found that she had a fever with chills and rigor during her 9th month of conception; however, currently she was afebrile. The mother's smear study and optimal test were negative for any malarial parasites.

DISCUSSION

Definition of congenital malaria is the presence of parasite (asexual stages) in the umbilical cord during childbirth or in a smear test of the newborn's blood within seven days of life. *Pfalciparum* is usually the most common cause of congenital malaria, followed by *P.vivax* is most prevalent in the Southeast Asian region. *P.vivax* is the most common cause of congenital malaria in European countries while in India and Africa, *P.falciparum* is the most common cause. Almost 1/3 of the women acquiring the infection at the time of pregnancy will have the placental infection. Usually there is self resolution of the infection in 93% of neonates in endemic region due the action of maternal serum antibodies against the parasite and also due to slowing of the rate of parasite development which is because of the fetal haemoglobin (FHb). As malaria is a rare presentation in newborn, majority

of the cases are diagnosed accidentally on smear study as a part of routine sepsis workup.

There is a non-specific clinical presentation in case of congenital malaria. When fever, pallor and reduced haemoglobin, and clinical splenomegaly are present, congenital malaria is to be suspected. The case discussed here illustrates the need to look for congenital malaria as an important part of the diagnosis of neonatal sepsis in infants born in areas with a high incidence of malaria or a history of malaria in the mother during pregnancy.

Maternal blood transfusions into the fetal circulation during childbirth or pregnancy are through different pathways; chorionic villi (direct transmission) and PROM (direct transmission). The fetus has the capacity to resist malarial infection. The protective factors against the infection are placental barrier, maternal antibodies transfer, and FHB. Congenital malaria can also occur, even if the mother didn't have malarial infection during the time of pregnancy. In this case, the mother is expected to develop a form of malaria that resolves spontaneously and is not detected in the 9th month of pregnancy. Lack of parasites in the maternal blood and HRP2 (histidine-rich parasite) antigens in the blood indicates that there is a local infection of the placenta and has been resolved. The onset of symptoms in congenital malaria varies from birth to a few weeks; 21 days of life is the median age of presentation according to current literature.

Drug of choice in treating congenital malaria is chloroquine. The infection in neonates is due to the transmission of infected erythrocytes and not the forms that invade the liver. Hence the treatment of exoerythrocytic stages is not required.

This case was diagnosed accidentally on peripheral blood study. Therefore, it is always better to examine

the smear study to the fullest in all cases suspected of neonatal sepsis. To conclude, malaria should be blamed on all newborns who are plagued by complaints of fever and splenomegaly from flu-like areas. Early diagnosis can prevent unnecessary use of antibiotics and infant mortality.

REFERENCES

1. Yeager AS. Protozoan and helminth infections. In: Remington JS, Klein JO, editors. Infectious Diseases of the Fetus and Newborn Infant. 2nd ed. Philadelphia: WB Saunders; 1983. pp. 563-9.
2. Nosten F, McGready R, Simpson JA, et al. Effects of Plasmodium vivax malaria in pregnancy. Lancet 1999 Aug;354(9178):546-9. [https://doi.org/10.1016/S0140-6736\(98\)09247-2](https://doi.org/10.1016/S0140-6736(98)09247-2)
3. Covell G. Congenital malaria. Tropical Diseases Bulletin 1950;47(12):1147-67.
4. Akindele J A. Sowunmi A, Abohweyere AE. Congenital malaria in a hyperendemic area: a preliminary study. Ann Trop Paediatr 1993;13(3):273-6. <https://doi.org/10.1080/02724936.1993.11747658>
5. McGregor IA. Epidemiology, malaria and pregnancy. Am J Trop Med Hyg 1984 Jul;33(4):517-25. <https://doi.org/10.4269/ajtmh.1984.33.517>
6. Santhanakrishnan BR, Parthasarathy A, Bhavani CR, Ramesh S. Profile of malaria in Madras. Indian J Pediatr 1985 May;52(3):249-55. <https://doi.org/10.1007/BF02754851>
7. Kothare SV, Kallapur SG, Irani SF, Prabhu SB, Gangal PS, Agarwal GJ. Congenital malaria (a report of two cases). J Postg Medicine 1987 Jul;33(3):158-61.
8. Gandhi A, Garg K, Wadhwa N. Neonatal plasmodium vivax malaria: an overlooked entity. J Infect Dev Ctries 2011 Jul;5(6):489-92. <https://doi.org/10.3855/jidc.1623>

CONFLICT OF INTEREST

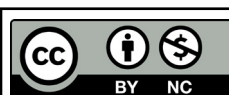
Authors declare no conflict of interest.
GRANT SUPPORT AND FINANCIAL DISCLOSURE
None declared.

AUTHORS' CONTRIBUTION

The following authors have made substantial contributions to the manuscript as under:

Conception or Design:	KGPG
Acquisition, Analysis or Interpretation of Data:	KGPG, KNC, SJ
Manuscript Writing & Approval:	KGPG, KNC, SJ

All the authors agree to be accountable for all aspects of the work in ensuring that questions related to the accuracy or integrity of any part of the work are appropriately investigated and resolved.



Copyright © 2021. Kalathil Gopalakrishna Pillai Gopikrishnan, et al. This is an Open Access article distributed under the terms of the Creative Commons Attribution-NonCommercial 4.0 International License, which permits unrestricted use, distribution & reproduction in any medium provided that original work is cited properly.