

# TURNER'S SYNDROME

Mohammad Noor, Shahid Abdullah, Sultan Mahmood

Department of Medicine, Khyber Medical College, Peshawar, Pakistan

## ABSTRACT

20 years old lady presented with primary infertility. History also revealed primary amenorrhea. Findings on her physical examination included short stature, cubitus valgus, slightly webbed neck, poorly developed secondary sexual characters, broad chest with widely spaced nipples, absence of pubic and axillary hair, short metacarpals and metatarsals. Except for the above, her systemic examination was unremarkable. A gynecological examination failed to reveal any abnormality. Ultrasound abdomen revealed streak gonads with small atrophic uterus. Plasma FSH and LH were high with low estrogen levels i.e. hypergonadotrophic hypogonadism. Karyotyping confirmed the diagnosis of Turner's syndrome with mosaicism: 45 X/46 Xi).

**Key words:** Turner's syndrome, Hypergonadotrophic hypogonadism, Primary infertility.

## INTRODUCTION

Turner's syndrome, a disorder of females is characterized by the absence of all or part of a normal second sex chromosome, leading to a constellation of physical findings that often includes congenital lymphedema, short stature, and gonadal dysgenesis.<sup>1,2,3</sup>

Turner's syndrome occurs in 1 in 2,500 to 1 in 3,000 live-born girls. Approximately half have monosomy X (45,X), and 5 to 10 percent have a duplication (isochromosome) of the long arm of one X (46,X,i(Xq)). Most of the rest have mosaicism for 45,X, with one or more additional cell lineages.

The presentation of Turner's syndrome varies at different ages. The diagnosis should be considered in a female fetus with hydrops, increased nuchal translucency, cystic hygroma, or lymphedema.<sup>4</sup> At any age, Turner's syndrome may be difficult to recognize clinically because the characteristic facial features can be subtle. Key clinical features of Turner's syndrome are lack of breast development or amenorrhea, with elevated follicle-stimulating hormone levels by 14 years of age; and infertility in women. Other characteristics of Turner's syndrome include short stature, webbed neck, low posterior hairline, misshapen or rotated ears, a narrow palate with crowded teeth, a broad chest with widely spaced nipples, cubitus valgus, hyperconvex nails, multipigmented nevi, pubertal delay, and cardiac malformation.<sup>5</sup>

One third of patients with Turner's syndrome have a cardiac malformation; 75 percent of these having coarctation of aorta or bicuspid aortic valve.<sup>6</sup> Progressive aortic root dilatation or dissec-

tion can also occur, particularly in patients with a bicuspid valve, coarctation or untreated hypertension.<sup>7,8</sup> Patients with Turner's syndrome often have an atherogenic cardiovascular risk factor profile.<sup>10</sup> Other potential complications of Turner's syndrome include strabismus, sensorineural hearing loss, recurrent otitis media, orthodontic anomalies, renal malformations (e.g., horseshoe kidney, duplicated or cleft renal pelvis), autoimmune thyroiditis, celiac disease, congenital hip dysplasia, and scoliosis.<sup>9</sup>

Girls with Turner's syndrome typically have normal intelligence (i.e. mean full scale IQ of 90); however, they may have difficulty with nonverbal, social, and psychomotor skills. If development is frankly delayed, an alternative explanation should be considered, along with prompt referral for early intervention.<sup>10,11</sup>

More than one half of patients with the condition will have a missing X chromosome (45,X) in all cells studied or a combination of monosomy X and normal cells (45,X/46,XX; mosaic Turner's syndrome). A mosaic result does not necessarily predict severity because karyotyping only investigates lymphocytes, not the relevant tissues like brain, heart and ovaries.

A karyotype is obtained by sending whole blood, at room temperature in a greentop sodium heparin tube to the laboratory. It takes about a week time. If an urgent result is needed (e.g. because of parental anxiety or a critical clinical situation), X-specific fluorescence in situ hybridization can confirm monosomy X in less than 24 hours.

Although 45,X is the karyotype typically seen in patients with Turner's syndrome, other sex chro-

mosome anomalies such as isochromosome Xq, ring X, deletion Xp, or an abnormal Y chromosome can also cause the condition.<sup>4</sup> Patients with Y chromosome material have a 12 percent risk of gonadoblastoma and must be referred for imaging studies and laparoscopic removal of testicular tissue (i.e., gonadectomy).<sup>10</sup>

## CASE HISTORY

A 20 years old lady presented to our unit with the complaint of primary amenorrhea and inability to conceive after 4 years of marriage. Detailed obstetric history revealed that she never had a menarche or vaginal spotting. There was no history of cyclical abdominal pain or nodules on the skin. She did not experience dyspareunia and was not using any type of contraception. She and her husband were trying to conceive since they married but were so far unable to achieve pregnancy. Patient did not report any history of chemotherapy, radiotherapy, trauma or surgery to gonads. Past medical history was negative for mumps, tuberculosis, or any major systemic illness including asthma, malabsorption, celiac disease, cystic fibrosis, renal failure, or HIV infection.

Patient was a product of non-consanguineous marriage. She was born to a full term pregnancy with normal vaginal delivery at home. There was no history of obstructed labor, ante-partum or post-partum hemorrhage, congenital birth defects, birth asphyxia or neonatal jaundice. She was adequately vaccinated against polio, tuberculosis and DPT. She was breast fed for 13 months before being weaned off. She achieved her early developmental milestones (neck holding, walking, talking) reasonably well within time. However, patient never developed axillary or pubic hair. On close inquiry, it was revealed that she was considerably shorter than her peers. The patient reported that she started lagging behind in her height as she approached 8<sup>th</sup> or 9<sup>th</sup> year of life. She also noticed that her secondary sexual characters failed to develop properly as she reached her pubertal age. She never had any type of schooling but was of normal intelligence and did her house chores without discernible difficulty. She mingled with her peers and had no obvious problem with social interactions.

She had three brothers and four sisters who were doing well. She belonged to a poor socioeconomic background. However, there was no history of worm infestation or major nutritional deprivation. She was not an addict and did not take any medications except for occasional painkillers.

On examination, the patient was hemodynamically stable. She had a blood pressure of 115/

75 mmHg with no postural drop. Her pulse was 75/minute and regular and respiratory rate of 15/minute. Her O<sub>2</sub> saturation was 98% while breathing ambient air.

Findings on her physical examination included:

- Short stature with a height of 120 cm. (Figure-1)
- Cubitus valgus i.e wide carrying angles at the elbows. (Figure-1)
- Slightly webbed neck. (Figure-2)
- Poorly developed secondary sexual characters. (Figure-3)
- Broad chest with widely spaced nipples. (Figure-3)
- Absence of pubic and axillary hair. (Figure-4)
- Short metacarpals and metatarsals. (Figure-5 and 6)

Except for the above, her systemic examination was unremarkable. A gynecological examination failed to reveal any abnormality and there was no evidence of imperforate hymen.

Patient was provisionally diagnosed as "Delayed Puberty" and investigations were performed to find out the cause.

Baseline investigations were all normal. Plasma FSH and LH were high while estrogen levels were low. A radiograph of the hand revealed short metacarpals.

After having established that she had hypergonadotrophic hypogonadism, suggestive clinical features prompted the investigation of karyotyping, which confirmed the diagnosis of Turner's syndrome with mosaicism: 45 X/46 Xi). (Figure-7 and 8)

Ultrasound abdomen revealed streak gonads with small atrophic uterus. No renal pathology was seen. Echocardiography was normal. Thyroid function tests, liver function tests, lipid profile, serum calcium, serum alkaline phosphatase levels and PTH were all normal.

## DISCUSSION

Delayed diagnosis of Turner's syndrome in girls with short stature is typical. One study showed that the diagnosis is made on an average of seven years after short stature is clinically evident on female growth curves.<sup>12</sup> In a case series, 4 percent of girls referred for genetic evaluation of isolated short stature, regardless of familial background height, were diagnosed with Turner's syndrome.<sup>13</sup> More than 30 percent of the referred girls who had

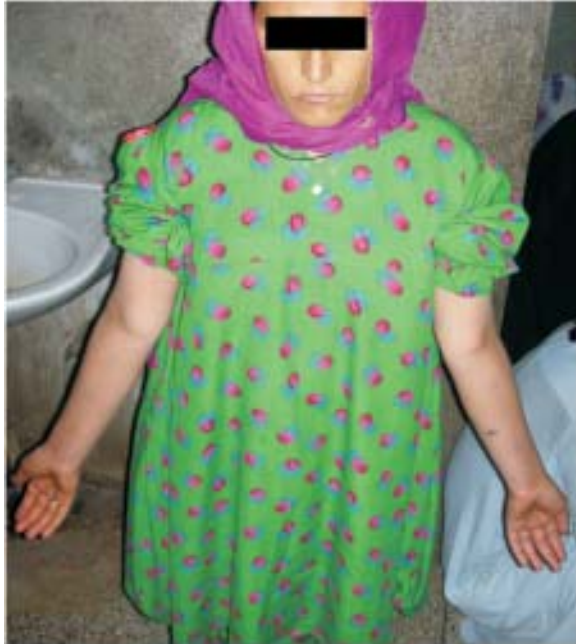

Fig-1: Short stature with cubitus valgus.

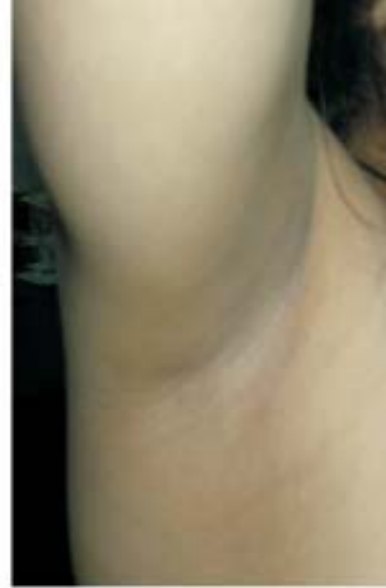

Fig-4: Absence of axillary hair

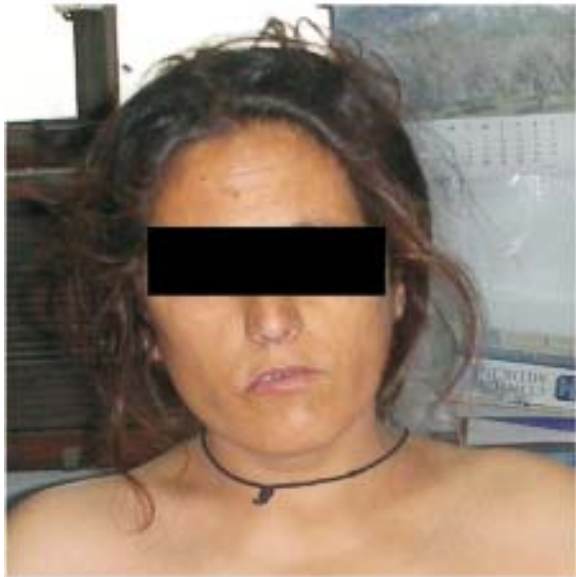

Fig-2: Webbing of the neck.

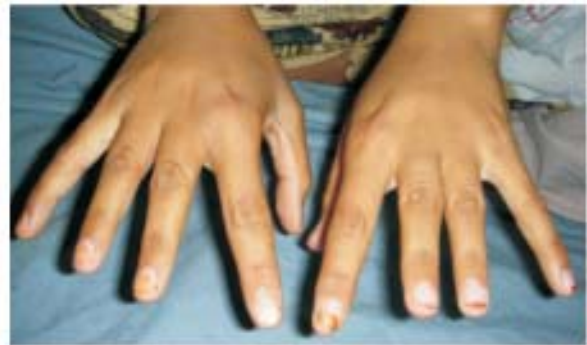

Fig-5: Short 3<sup>rd</sup> and 4<sup>th</sup> metacarpals.

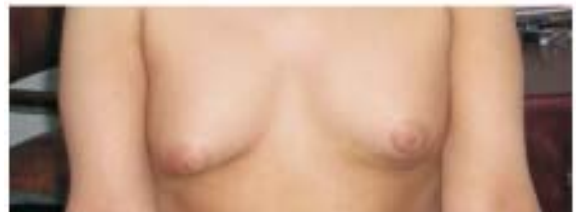

Fig-3: Broad chest with poorly developed breasts & widely spaced nipples.

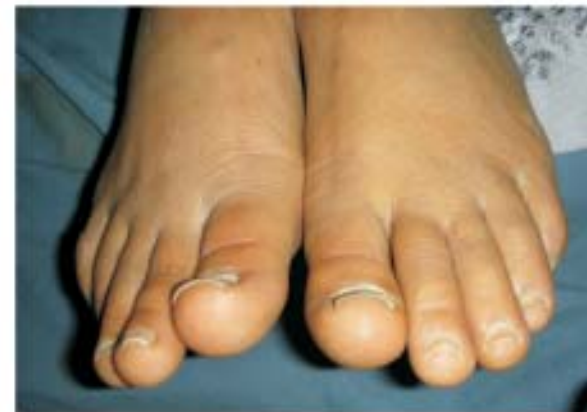

Fig-6: Short 4<sup>th</sup> and 5<sup>th</sup> metatarsals.

amenorrhea or suggestive phenotypic features had Turner's syndrome.<sup>14</sup> Karyotyping is indicated for girls with unexplained short stature (more than two standard deviations below the mean height for age).<sup>12,13</sup>

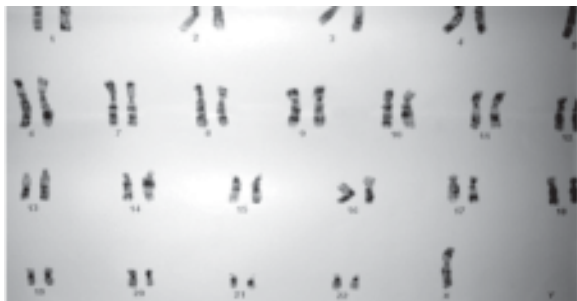


Figure-7: Karyotyping: 45 XO cell line.

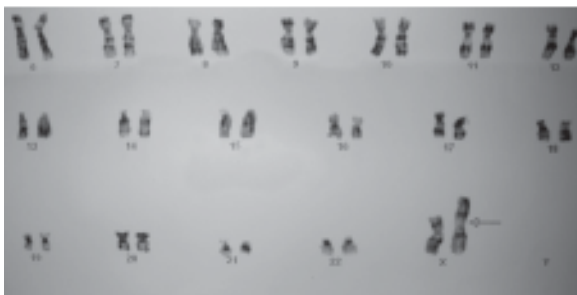


Figure 8: Karyotyping: 45 Xi cell line.

Given the complexity and multisystem nature of Turner syndrome, family physicians can play an important role in coordinating multidisciplinary management and in directly managing risk factors and complications (e.g., infertility, cardiovascular complications, osteoporosis). Controlled studies with patient-oriented outcomes such as morbidity, mortality and quality of life in patients with Turner's syndrome are generally lacking. However, the Turner Syndrome Consensus Study Group, sponsored by the National Institutes of Health's National Institute of Child Health and Human Development, has published comprehensive management guidelines based on collective expert opinion and a review of the existing literature.<sup>14-16</sup>

The key aspects of managing Turner's syndrome in children are cardiovascular monitoring and treatment of congenital heart disease; growth hormone therapy to augment linear growth (as early as 12 to 24 months of age) and supplemental estrogen therapy for sexual development and preservation of bone mineral density (typically initiated in the preteen years).<sup>16</sup> The mean adult height in patients with Turner's syndrome is 140 cm but with growth hormone and estrogen therapy, the average height increases to 150 cm.<sup>14,15,17</sup> Growth hormone therapy is typically discontinued after

the patient reaches a bone age of 14 years; sex hormone therapy is generally continued throughout life.<sup>14,15</sup>

Patients with Turner's syndrome require audiometry at diagnosis and periodically thereafter to assess for sensorineural or conductive hearing loss from recurrent otitis media; blood pressure measurement in all four extremities; and ongoing annual thyroid function, liver enzyme and fasting lipid and glucose monitoring. Infants and young children with Turner's syndrome should be examined with Barlow /Ortolani maneuvers for evidence of congenital hip dislocation and those older than one year should be referred to a pediatric ophthalmologist to assess for hyperopia and strabismus. Ultrasonography should be performed at diagnosis to assess for congenital renal malformations. Girls older than four years should have a tissue transglutaminase immunoglobulin A measurement every two to four years to detect celiac disease. Patients seven years or older need orthodontic evaluation for malocclusion or other tooth anomalies. Teenagers should be carefully monitored for scoliosis and kyphosis.

In adults, fertility and sexual development are often the major concerns for patients with Turner's syndrome. The ovaries develop but typically degenerate during fetal life or in the early childhood. However, spontaneous menstruation and childbirth occur in 2 to 5 percent of patient with Turner's syndrome, which may be explained by substantial 46,XX/45,X mosaicism, with normal cell populations existing in the ovaries.<sup>18</sup> Because spontaneous pregnancy is possible, patients should be counseled about birth control if sexually active.

Patients with Turner's syndrome are likely to ask their family physicians about reproductive potential and age-appropriate counseling about infertility treatments can markedly mitigate the adverse psychological impact of the diagnosis.<sup>11</sup> In vitro fertilization (using oocytes harvested and cryopreserved before ovarian regression is complete) is being studied in young women with Turner's syndrome.<sup>10</sup> Spontaneous or assisted pregnancy carries substantial risks; therefore, pre-conception counseling and cardiac echo-cardiography or magnetic resonance imaging (MRI) are essential. Primary care providers should monitor the pregnancy as part of a multidisciplinary team (e.g., high-risk obstetrics, cardiology, and reproductive endocrinology subspecialists).

In addition to the reproductive counseling, the adult treatment of Turner's syndrome includes management of atherogenic cardiovascular risk factors (e.g., hypertension, diabetes, hyperlipidemia); calcium and vitamin D supplementation to prevent osteoporosis; and ongoing sex hor-

mone therapy. A baseline dual energy x-ray absorptiometry scan to evaluate bone mineral density is recommended at the first adult visit. Adult women should continue to get high-quality echocardiography or MRI of the aorta every 5 to 10 years to assess the need for surgical correction of severe aortic root dilatation which occurs over time in 8 to 42 percent of patients.

The psychosocial impact of Turner's syndrome may be substantial for young girls and women. These effects may be caused by infertility; short stature; and impaired development of sexual characteristics and most importantly lack of libido.<sup>11</sup> Physicians should elicit specific concerns from patients, addressing them individually and should recommend comprehensive school-based psycho educational assessment.

## CONCLUSION

Delayed puberty is not an uncommon clinical problem and it is often disregarded as constitutional delay. It is stressed that strict clinical vigilance should be maintained and every case properly investigated in order to avoid missing a rare diagnosis such as Turner's syndrome. Recent advances in the medical science have enabled us to better help patients with Turner's syndrome, especially in the form of growth hormone and hormone replacement therapy. Furthermore, screening such patients for known associations carries the advantage of prophylactic interventions that in many situations may be life saving.

## REFERENCES

1. Turner HH. A syndrome of infantilism, congenital webbed neck, and cubitus valgus. *Endocrinology* 1938; 23: 566-74.
2. Ford CE, Jones KW, Polani PE, de Almeida JC, Briggs JH. A sex-chromosome anomaly in a case of gonadal dysgenesis (Turner's syndrome). *Lancet* 1959; 1: 711-3.
3. Elsheikh M, Dunger DB, Conway GS, Wass JA. Turner's syndrome in adulthood. *Endocr Rev* 2002; 23: 120-40.
4. Sanders RC, Blackmon LR. *Structural Fetal Abnormalities: The Total Picture*. 2nd ed. St. Louis, Mo.: Mosby, 2002: 15-16.
5. Jones KL, Smith DW. *Smith's Recognizable Patterns of Human Malformation*. 6th ed. Philadelphia, Pa.: Elsevier Saunders, 2006: 76-81.
6. Völkl TM, Degenhardt K, Koch A, Simm D, Dorr HG, Singer H. Cardiovascular anomalies in children and young adults with Ullrich-Turner syndrome the Erlangen experience. *Clin Cardiol* 2005; 28: 88-92.
7. Elsheikh M, Casadei B, Conway GS, Wass JA. Hypertension is a major risk factor for aortic root

dilatation in women with Turner syndrome. *Clin Endocrinol* 2001; 54: 69-73.

8. Mazzanti L, Cacciari E, for the Italian Study Group for Turner Syndrome (ISGTS). Congenital heart disease in patients with Turner syndrome. *J Pediatr* 1998; 133: 688-92.
9. Van PL, Bakalov VK, Bondy CA. Monosomy for the X-chromosome is associated with an atherogenic lipid profile. *J Clin Endocrinol Metab* 2006; 91: 2867-70.
10. Bondy CA, for the Turner Syndrome Consensus Study Group. Care of girls and women with Turner syndrome: a guideline of the Turner Syndrome Study Group. *J Clin Endocrinol Metab* 2007; 92: 10-25.
11. Sutton EJ, McInerney-Leo A, Bondy CA, Gollust SE, King D, Biesecker B. Turner syndrome: four challenges across the lifespan. *Am J Med Genet A* 2005; 139: 57-66.
12. Savendahl L, Davenport ML. Delayed diagnoses of Turner syndrome: proposed guidelines for change. *J Pediatr* 2000; 137: 455-9.
13. Moreno-Garcia M, Fernandez-Martinez FJ, Barreiro Miranda E. Chromosomal anomalies in patients with short stature. *Pediatr Int* 2005; 47: 546-9.
14. Hanton L, Axelrod L, Bakalov V, Bondy CA. The importance of estrogen replacement in young women with Turner syndrome. *J Womens Health* 2003; 12: 971-7.
15. Quigley CA, Crowe BJ, Anglin DG, Chipman JJ. Growth hormone and low dose estrogen in Turner syndrome: results of a United States multi-center trial to near-final height. *J Clin Endocrinol Metab* 2002; 87: 2033-41.
16. Rosenfield RL, Devine N, Hunold JJ, Mauras N, Moshang T Jr, Root AW. Salutary effects of combining early very low-dose systemic estradiol with growth hormone therapy in girls with Turner syndrome. *J Clin Endocrinol Metab* 2005; 90: 6424-30.
17. Stephure DK, for the Canadian Growth Hormone Advisory Committee. Impact of growth hormone supplementation on adult height in Turner syndrome: results of the Canadian randomized controlled trial. *J Clin Endocrinol Metab* 2005; 90: 3360-6.
18. Hovatta O. Pregnancies in women with Turner syndrome. *Ann Med* 1999; 31: 106-10.

## Address for Correspondence:

Dr. Mohammad Noor  
Assoc. Prof. Medicine  
Khyber Medical College  
Peshawar, Pakistan  
Cell: +923339108052  
E Mail: noorwazir1966@yahoo.com