

# MANAGEMENT OF THORACOLUMBAR SPINAL FRACTURES BY PEDICULAR SCREWS AND RODS

Mohammad Arif, Mohammad Inam, Abdul Satar, Mohammad Saeed, Mohammad Shabir

Department of Orthopaedics, Hayatabad Medical Complex Peshawar, Pakistan

## ABSTRACT

**Background:** There are different ways of management of spinal injuries including operative and non-operative. Operative management is indicated to minimize pain, stabilize spine, correcting and preventing subsequent spinal deformity, early mobilization, reduction of morbidity and improvement in neurological function. This study was conducted to determine the effectiveness of posterior spinal fixation of thoracolumbar spine.

**Material & Methods:** Seventy six patients with thoracolumbar spine fracture were managed surgically in Orthopedic Department of Hayatabad Medical Complex Peshawar from December 2003 to November 2007 by posterior spinal fixation with pedicular screws and rods.

**Results:** Out of seventy-six patients 36 had road traffic accident, 28 had a fall from a height and 12 were hit by a heavy falling object. Preoperative kyphosis was 27° averaged and postoperative was 7° averaged. The sagittal index was 26° averaged and postoperative was 12° averaged. More than half of the patients had no pain one year after surgery, while two (2.6%) had moderate to severe pain. Forty (52.6%) patients returned to the job they held before the fracture while ten (13.1%) were not able to do work. Complications observed were; Infection in eight (10.5 %) patients, pull out of upper screws in one patient, pull out of rod from screws in one patient and deep vein thrombosis in another one patient.

**Conclusion:** Posterior spinal fixation by pedicular screws gives rigid fixation with excellent result which enables patients to resume daily activities early.

**Key words:** Posterior spinal fixation, Pedicular Screw, Thoracolumbar Vertebra.

## INTRODUCTION

Spinal fractures are not uncommon occurrence<sup>1</sup>. Spinal injuries occur predominantly in young males and male to female ratio is four to one. Frequency of vertebral fractures increases with age due to osteoporosis<sup>2</sup> and decreasing bone density<sup>3</sup>. Neurological deficit occurs in 26 % of these injuries. Traumatic spinal cord injury is estimated to be 29-50 cases per million populations per year world wide<sup>4</sup>. The international frequency of spinal fractures is difficult to determine due to differences in data collection and reporting among countries<sup>2</sup>. In the trauma patients thoracic and lumbar fractures occur in 15000 individuals annually in United States, and account for 30-60% of all spinal injuries. In Pakistan significant number of people suffers from spinal injuries every year<sup>4</sup>.

Causes of spinal injuries are motor vehicle accidents, fall from height, hit by a heavy falling object, gunshot wounds, sports accidents, industrial accidents and agriculture accidents.<sup>5,6</sup>

There are different types of management of spinal injuries including operative and non-operative<sup>7</sup>. Non-operative treatment can be employed

in patients with less vertebral body compression using thoracolumbar orthosis and restriction of activities<sup>8</sup>.

Significant development in management of spinal injuries occurred in 20<sup>th</sup> century. The era of 1940s was remembered for the use of rods, wires, screws, inter body fusion and bone grafting<sup>2</sup>. 1980 produced proliferation of modern spinal instrumentation system like pedicle screws, rods and multiple hooks<sup>9</sup>.

Surgery is indicated to minimize pain, stabilize spine, correcting and preventing subsequent spinal deformity, early mobilization, reduction of morbidity and improvement in neurological function<sup>10</sup>. Posterior internal fixation with titanium and stainless steel pedicle screws and rods is becoming increasingly popular which are longitudinally anchored to the spine<sup>10,11</sup>. In posterior inter transverse fusion, bone grafts are placed. In posterior interbody fusion technique, decompression is done through a standard posterior laminectomy<sup>12, 13</sup>.

The objective of this study is to determine the effectiveness of posterior spinal fixation in main-

taining the stability and correction of deformity of thoracolumbar spine.

### MATERIAL AND METHODS

Seventy six patients with thoracolumbar spine fracture were managed surgically in Orthopedic Department of Postgraduate Medical Institute, Hayatabad Medical Complex Peshawar from December 2003 to November 2007 by posterior spinal fixation with pedicular screws and rods.

Patients with unstable fractures were included in the study while patients with bed sores and unfit for anesthesia were excluded.

All patients with thoracolumbar spinal fracture reporting to Orthopedic Department were admitted and selected according to inclusion and exclusion criteria. The purpose of the study was explained to them; their cooperation sought and written informed consent was taken. After getting informed consent, they were operated by posterior approach and internal fixation was done using polyaxial pedicular screws and rods system made locally from Titanium. On stabilization of their condition post operatively, they were referred to physiotherapy and rehabilitation centre with instructions. The patients were followed up for a period of 1 year after surgery, and their data were collected.

The data include pain and mobility, deformity, correction of deformity and complications. The pain was recorded using Dennis Pain Scale<sup>14</sup> (Figure-1) and mobility (resumption of work) by Dennis Work Scale<sup>14</sup> (Figure-2). Radiological evidence of deformity and correction of deformity were evaluated by measuring Cobb angle<sup>14</sup>, anterior and posterior vertebral heights (AVH & PVH), sagittal index<sup>15</sup> and posterior column injury using plain radiographs. The data was analyzed

DENNIS PAIN SCALE	
<b>P1 :</b>	No pain
<b>P2 :</b>	Occasional minimal pain; no need for medication
<b>P3 :</b>	Moderate pain, occasionally medications e no interruption of work or activities of daily living
<b>P4:</b>	Moderate to severe pain, occasionally absent from work; significant changes in activities of daily living
<b>P5 :</b>	Constant, severe pain; chronic pain medications

Fig 1: Dennis Pain Scale.<sup>14</sup>

DENNIS WORK SCALE	
<b>W1 :</b>	Return to previous employment (heavy labor) or physically demanding activities
<b>W2 :</b>	Able to return to previous employment (sedentary) or return to heavy labor with restrictions
<b>W3 :</b>	Unable to return to previous employment but works full time at new job
<b>W4 :</b>	Unable to return to full time work
<b>W5 :</b>	No work, completely disabled

Fig 2: Dennis Work Scale.<sup>14</sup>

using SPSS version 10, and results presented as frequencies and mean values  $\pm$  standard deviation in the form of tables. Pair t-test was applied when and where necessary during analyzing the data. The level of significance was chosen as 0.05.

### RESULTS

Total seventy six patients were included in the study in which 49 were male and 27 were female. The maximum age was 65, minimum was 20 and average was 32 years. In 36 patients the injury was caused by a road traffic accident, in 28 by a fall from a height and in 12 the patient was hit by a heavy falling object. In twelve patients the fracture was located at T11, in 18 at T12, in 22 at L1, in 20 at L2 and in 4 at L3 vertebra. There were associated distal radius fractures in four patients, radius and ulna fracture in one, distal tibial fractures in five, calcaneal fracture in seven, clavicle in one, humerus in one and pelvic fractures in eight patients.

Denis classification was used in our study. The four major types of fractures were compression fractures 56(73.68%), burst fractures 12(15.78%), flexion-distraction injuries 4(5.26%), and fracture-dislocations 4(5.26%).

The mean kyphosis was 27° preoperatively. Immediately after surgery, the correction of kyphosis averaged was 7° which was the same at final follow up (Figure 3 and 4). The sagittal index of the fractured vertebra ranged from 12° to 36° in the preoperative period (mean: 26°), from 5° to 15° in the immediate post-operative period (mean: 8°) and from 5° to 20° (mean: 12°) at the final evaluation one year after surgery.

Vertebral body height ranged from 6 millimeter (mm) to 13 mm in the preoperative period. Postoperatively the vertebral height ranged from

18 to 22 mm (mean: 15mm) which was almost the same as of neighboring vertebra. There was a significant difference between preoperative and immediate postoperative values.

Evaluation of pain according to the Dennis scale <sup>14</sup> showed that 44 (57.9%) patients had no pain one year after surgery, 20 (26.3%) had minimal pain not requiring anti-inflammatory drugs, 10 (13.1%) had moderate pain requiring the occasional use of analgesics, 2 (2.6%) had moderate to severe pain, with occasional loss of work days and significant changes in daily activities (Table 1).

**Table 1: Evaluation of post operative pain according to the Dennis Pain Scale. (n= 76)**

No. of patients	Characteristics of pain
44 (57.9%)	P 1: No pain
20 (26.3%)	P 2: Minimal pain not requiring analgesics
10 (13.1%)	P 3: Moderate pain requiring occasional analgesic
2 (2.6%)	P 4: Moderate to severe pain with occasional loss of work days

Evaluation of the ability to work (mobility) by the Denis scale showed that 40 (52.6%) patients had returned to the job they had held before the fracture, 18 (23.7%) did not return to their previous job but are currently working full time on another job, 8 (10.5%) are working with limitations on a part time basis and 10 (13.1%) are not working (not able to work) (Table 2).

**Table 2: Evaluation of post operative ability to work according to the Dennis Work Scale. (n= 76)**

No. of patients	Characteristics of Work
40 (52.6%)	W 1: Returned to the job they held before
18 (23.7%)	W 3: No previous job but working full time another job
8 (10.5%)	W 4: Working with limitations on a part time basis
10 (13.1%)	W 5: Not working

There were eleven complications observed in all patients. Infection was observed in eight patients in whom the wound was opened, thorough debridement was done and the wound healed with-

out removing the implants. There was pull out of upper screws from pedicles in one patient, pull out of rod from screws in one patient (figure 5) and deep vein thrombosis (DVT) in another one patient who were treated accordingly. (Table-3)

**Table 3: Complications. (n=76)**

Complications	Percentage
Infection	8 (10.5%)
Screw pull out	1(1.3%)
Pull out of rods from screw	1(1.3%)
Deep vein thrombosis (DVT)	1(1.3%)

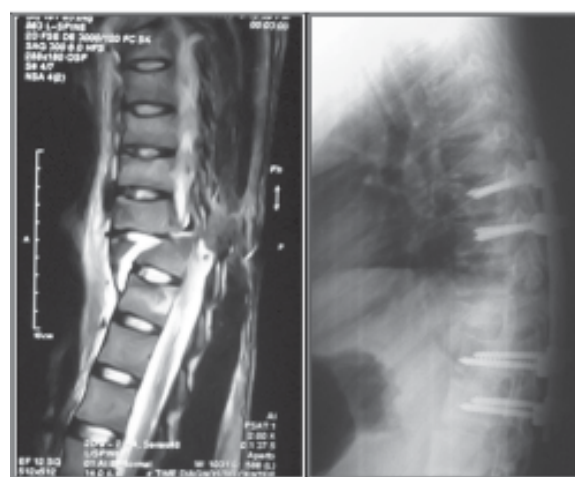


Fig 3: Preoperative MRI and Post operative X Rays of forty two years old patient with fracture dislocation Of Thoracolumbar Spine with complete transection of the cord.

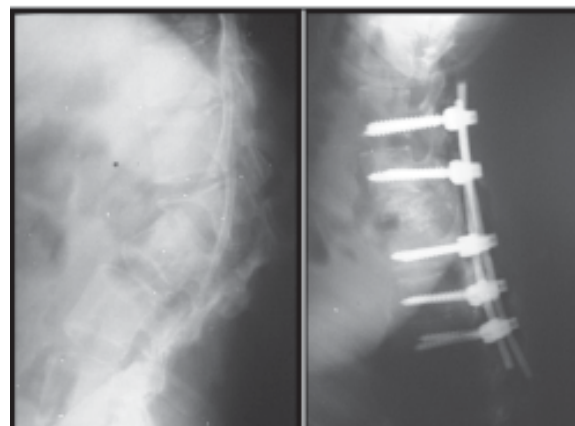


Fig 4: Pre and Post operative X Rays of twenty eight years old patient with three months old fracture dislocation of Thoracolumbar Spine with cord transection.

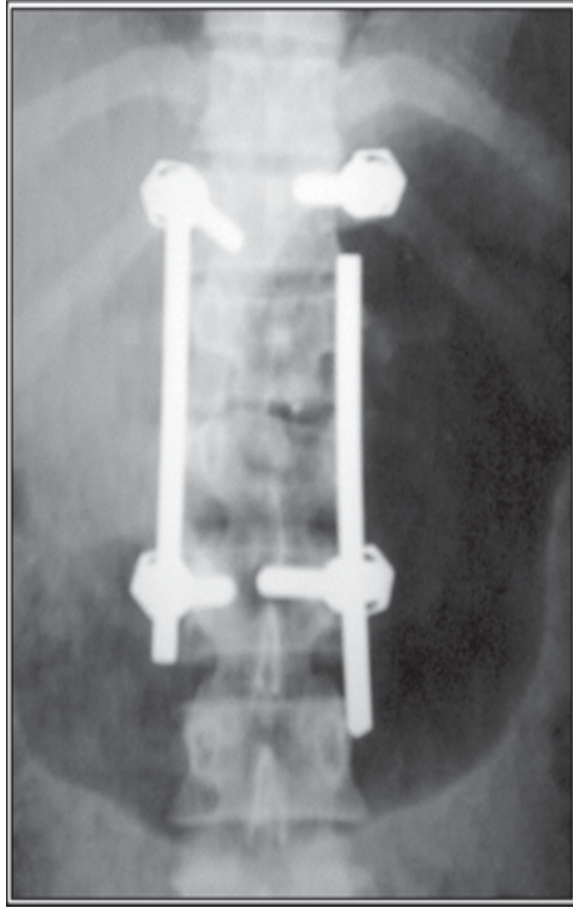


Fig 5: Pull out of rod from screw.

## DISCUSSION

There is no agreed surgical procedure for spinal fracture but pedicular screws and rod fixation is practiced nowadays widely.<sup>16-19</sup> Among the pedicular screws the polyaxial are more commonly used.<sup>19,20</sup>

Radiological assessment was most markedly observed post operatively. In one study it was shown that post operatively kyphosis improved at an average of 7.5 degrees and at follow-up examination angle of kyphosis was at an average of 6.5 degrees.<sup>17</sup> In another study the correction of kyphosis was 98% averaged post operatively<sup>18</sup> while in our study correction of kyphosis was 92% averaged. Helton et al<sup>22</sup> had observed that the sagittal index of the fractured vertebra improved from 8° to 32° (mean 20°) during the preoperative period to 3° to 25°(mean 14°) in the immediate postoperative period. In our study the sagittal index of the fractured vertebra ranged from 12° to 36° in the preoperative period (mean: 26°), from 5° to 15° in the immediate postoperative period (mean: 8°) and from 5° to 20° (mean: 12°) at the final evaluation one year after surgery. There was a signifi-

cant difference between preoperative and immediate postoperative values

Denis pain scale showed that 44% patients had no pain and 17% had moderate to severe pain two years after surgery in Helton et al<sup>22</sup> study while in our study 57.9% patients had no pain one year after surgery, 2.6% had moderate to severe pain, with occasional loss of work days and significant changes in daily activities.

Employment of the patients are the main concern and most of the patient were anxious wither they will resume their duties or not. In Helton et al<sup>22</sup> study 50% patients had returned to the job they held before and 17% were not able to resume their job while in our study 52.6% patients returned to the job they held before the fracture and 13.1% had lost their jobs and was not able to work. Other complications like DVT, pullout of screws and implant failure was almost the same with studies done elsewhere.<sup>16-19</sup>

In our environment the infection was the most common and dreadful complication which was observed in eight (10.5%) patients while in other studies it was less than that.<sup>20,21,22</sup>

Starkweather<sup>23</sup> observed that decompression combined with posterior spinal fixation by pedicular screws and rods had excellent results in degenerative spondylolisthesis because instrumentation increases the intervertebral distance to pre-disease height, allows complete and longer lasting spinal root decompression and maintains lordosis of the lumbar spine.<sup>20</sup>

## CONCLUSION

Advances in posterior spinal fixation techniques allow patients to spend less time in the hospital, experience less pain, early resumption to pre disease state of work, and has quicker recovery time. In our society a dependent person is more than a diseased itself and if these patients are not treated properly, they will not only loose their employment but will be a permanent burden and nuisance for their family. Fixation of the spine can make the nursing care easier in paraplegic patients because these patients require vigilant nursing care to ensure optimal recovery.

## REFERENCES

- 1 Bolesta MJ, Rehtine II GR. Fractures and dislocations of the thoracolumbar spine. In: Bucholz RW, Hechman JD. Rockwood and Green's Fractures in adults. 6<sup>th</sup> edition. USA. Lippincott Williams & Wilkins 2008: 1405-65.
- 2 Vaccaro AR, KimDH, BrodkeDS, Harris M, Chapman JR, Schildhauer T, Routt ML, Sasso RC. Diagnosis andmanagement of thoracolum-

- bar spine fractures. *Instr Course Lect* 2004; 53:359–73.
- 3 Mirza SK, Chapman JR. Principles of management of spine injury. In: Bucholz RW, Heckman JD. *Rockwood and Green's Fractures in adults*. 6<sup>th</sup> edition. USA. Lippincott Williams & Wilkins 2008; 1295-1323.
  - 4 Butt RM, Shams S, Habib A, Raja IA, Sarwar A, Ahmed A. Epidemiology of spinal injuries. *Pakistan J Neurol*. 1997; 3: 20-5.
  - 5 Bensch FV, Koivikko MP, Kiuru MJ, Koskinen SK. The incidence and distribution of burst fractures. *Emerg Radiol* 2006; 12:124–9.
  - 6 Vaccaro AR, Kim DH, Brodke DS, Harris M, Chapman J, Schildhauer T et al. Diagnosis and management of thoracolumbar spine fractures. *J Bone & Joint Surg Br* 2003; 85:2456-70.
  - 7 Berry GE, Adams S, Harris MB. Are plane radiographs of spine necessary after blunt trauma? Accuracy of screening torso computer tomography in thoracolumbar spine fracture diagnosis. *J Trauma*. 2005; 59: 1410-3.
  - 8 Karaikovic EE, Pacheco HO. Treatment options for thoracolumbar spine fractures. *Bosn J Basic Med Sci* 2005; 5: 20-6.
  - 9 Kervin AJ, Frykberg ER, Schnico MA. The effect of early spinal fixation on non neurologic outcome. *J Trauma* 2005; 58: 15-21.
  - 10 Krbec M, Stulik J. Treatment of thoracolumbar spinal fractures using internal fixations. *Acta Chir Orthop Traumatol Cech* 2001; 68: 77-84.
  - 11 Razaq M, Mahmud MM, Hayzam MY, Omer A. Short segment posterior instrumentation, reduction and fusion of unstable thoracolumbar burst fractures-a review of 26 cases. *Med J Malaysia*. 2000; 55: 9-13.
  - 12 Hiwatashi A, Sidhu R, Lee RK, et al. Kyphoplasty vs. vertebroplasty to increase vertebral body height a cadaveric study. *Radiology* 2005; 237: 1115-9
  - 13 Leventhal MR. Fractures, dislocations and Fracture-dislocations of spine. In: Canale ST. *Campbell's Operative Orthopedics*. 10<sup>th</sup> edition. USA. Mosby 2003: 1597-1690.
  - 14 Farcy JP, Weidenbaunn M, Glassman SD. Sagittal index in management of thoracolumbar burst fractures. *Spine* 1990; 15: 958–65.
  - 15 Defino HL, Scarparo P Fractures of thoracolumbar spine: Monosegmental fixation. *Injury* 2005; 36:90–7.
  - 16 Steib JP, Aoui M, Mitulescu A, Bogosin I, Chiffolot X, Cognet JM. Thoracolumbar fractures surgically treated by “in situ” contouring. *Eur Spine J* 2006; 12:1823–32.
  - 17 Dai L-Y, YaoW-F, Cui Y-M, Zhou Q Thoracolumbar fractures in patients with multiple injuries: diagnosis and treatment – a review of 147 cases. *J Trauma* 2004; 56: 348–55.
  - 18 Thomas KC, Bailey CS, Dvorak MF, Fisher KB. Comparison of operative and nonoperative treatment for thoracolumbar burst fractures in patients without neurological deficit: a systematic review. *J Neurosurg Spine* 2006; 4:351–8.
  - 19 Khan I, NadeemM, Rabbani ZH. Thoracolumbar junction injuries and their management with pedicle screws. *J Ayub Med Coll Abbottabad* 2007; 19:7-10
  - 20 Afzal S, Mir MR, Halwai MA, Shabir A. Steffee (VSP) instrumentation for the surgical management of thoracolumbar spinal fractures.(a study of 20 cases). *JK-Practitioner* 2002; 94: 227-30
  - 21 Tezer CM, Ozturk M, Aydogan C, Mirzanli U, Talu AH .Surgical outcome of thoracolumbar burst fractures with flexion–distraction injury of the posterior elements. *International Orthopaedics* 2005; 29: 347–50
  - 22 Helton LA, Defino Fabiano RTC. Low thoracic and lumbar burst fractures: radiographic and functional outcomes *Eur Spine J* 2007 16:1934–1943.
  - 23 Starkweather A. Posterior Lumbar Interbody Fusion. An Old Concept with New Techniques. *J Neurosci Nurs* 2006; 38: 13-30.

**Address for Correspondence:**

Dr Mohammad Inam  
 House-5, Street-1, Sector K-2  
 Phase-3, Hayatabad  
 Peshawar, Pakistan  
 E-mail: dr\_mohammadinam@yahoo.co.uk