

CONGENITAL LOBAR EMPHYSEMA

Zahid Gul, Fahad Liaqat, Huma Ambreen Khan, Syed Zia UI Haq, Momina Tehreem
Rehman Medical Institute, Peshawar, Pakistan

ABSTRACT

Congenital lobar emphysema is a rare form of congenital malformation of the lungs characterized by over distension of a lobe of lung due to partial obstruction of the bronchus. The case that we are reporting is a 7 months baby admitted in the pediatric department with symptoms and signs of bronchiolitis/ bronchopneumonia. Chest x-ray showed partial consolidation of right upper and lower lobes and lobar emphysema of the left upper lobe. Computerized tomography of thorax showed emphysema of the left upper lobe. The baby was treated conservatively and discharged home safely followed by regular follow up visits.

KEY WORDS: Congenital emphysema; Emphysema.

This article may be cited as: Gul Z, Liaqat F, Khan HA, UI Haq SZ, Tehreem M. Congenital lobar emphysema. Gomal J Med Sci 2013; 11:236-8.

INTRODUCTION

Congenital lobar emphysema (CLE) is a rare malformation of lung development which may be the cause of respiratory insufficiency especially in suckling child that calls for urgent diagnosis and management.¹ It is caused by hyperinflation of the lung lobe with compression of normal lung parenchyma and contralateral displacement of the mediastinum.² The pathology is usually the deficiency in cartilage of the bronchial wall.³

Over distension of the pulmonary lobe is secondary to partial bronchial obstruction⁴. Most common effected lobe is left upper lobe followed by right upper lobe and right middle lobe but any lobe may be affected. There is inspiratory air entry but collapse of narrow bronchial lumen during expansion. The bronchial defect results in lobar air trapping.⁴

CLE is an uncommon but potentially life threatening abnormality affecting infants and patients often present within first 6 months of life with recurrent respiratory distress.⁵ Chest x-ray and CT scan of thorax are diagnostic and show hyperlucent affected lobe with herniation of the lobe to the opposite side, shifting of the mediastinum to the opposite side and collapse of the remaining part of the ipsilateral lung.⁶

Concomitant congenital heart disease (CHD) is not uncommon in CLE. In the literature a 12 to 20% concomitant rate is given.⁷ The underlying CHD, especially in infants with unusual respiratory distress symptom, should be kept in mind.⁷

The management of congenital lobar em-

physema has traditionally been surgical but due to advancement in imaging techniques, this lesion is frequently diagnosed in either asymptomatic or mildly symptomatic infants, prompting to adopt more conservative approach to these children.⁸ We will like to share with reader our experience of successfully managing a case of CLE.

CASE PRESENTATION

A 7 months old male patient from Malakand division of Khyber Pukhtunkhwa admitted in the Pediatric Department of RMI, Peshawar through a consultant OPD with presenting complaint of fever, cough, noisy chest and reluctant to feed for a period of one week. There was no history of jaundice, convulsion and sign of heart failure.

He was from a good socioeconomic status. The antenatal history was unremarkable. Ultrasound was not done at that time and baby was delivered at term through normal vaginal delivery in a hospital, the baby was breast fed till 3 months, later on started with formula milk.

On examination initially the baby was in mild respiratory distress, respiratory rate was 62/ minute, heart rate was 122/ minute, facies were normal and weight was 8.3 kg (15 centile) and head circumference of 43 cm (15 centile). There was no jaundice, hepatomegaly, convulsion and sign of heart failure.

Examination of respiratory system revealed bilateral wheezy chest with occasional crepts and decreased movement of left upper lobe with diminished breath sound, trachea was shifted to right and vocal resonance was decreased on the left side.

Chest x-ray showed partial consolidation of the right upper lobe and bilateral lower lobes and emphysema of the left upper lobe. (Fig. 1)

Corresponding author:

Zahid Gul, Trainee Medical Officer
Rehman Medical Institute, Peshawar pakistan.
e-mail: gulljee92@gmail.com

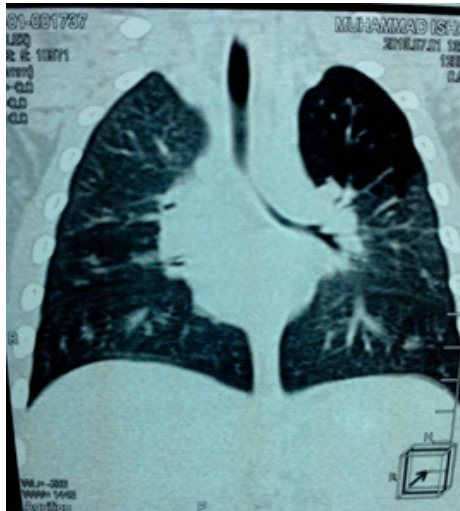


Figure 1: Chest x-ray of the child showing emphysema of the left upper lobe.

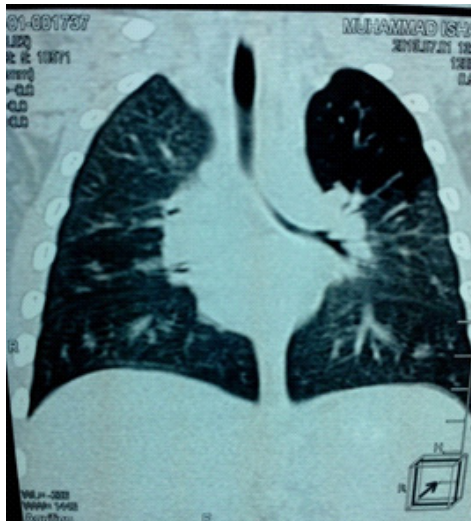

Fig. 2: CT thorax of the child showing lobar emphysema of the left upper lobe and partial obliteration of left upper lobe bronchus.

CT thorax showed congenital lobar emphysema left upper lobe and partially obliterated left upper lobe bronchus. (Fig. 2)

DISCUSSION

Congenital lobar emphysema is characterized by over inflation of the pulmonary lobe (gas trapping) and is caused by localized bronchial obstruction.^{9,10} The causative factor can be found only in half of the cases which include either partial bronchial obstruction or intrinsic alveolar disease.

In the partial bronchial obstruction there is cartilage abnormalities such as completely absent, hypoplastic, flaccid, immature cartilage; however,

bronchomalacia is the most common abnormality¹¹ while in the intrinsic alveolar disease there is tears in the alveolar walls or enlarged pores of Kohn; abnormal collagen deposition in the alveolar walls and supporting stroma.^{3,11,12,13} There are some case reports showing that congenital cytomegalovirus infection may play some role in development of congenital lobar emphysema.¹⁴ Congenital lobar emphysema almost always involve one lobe, with 47% rates of occurrence in the left upper lobe¹⁰, the case that we are presenting has involvement of the left upper lobe while in some cases bilateral involvement can occur with severe respiratory distress, which needs urgent surgical intervention.¹⁵ Acute development of severe respiratory distress necessitating emergency surgical intervention occurs in about 12% of patients and is often associated with acute upper respiratory tract infection.¹¹

Congenital lobar emphysema most often detected in the neonates or antenatally; however, less severely affected patients may present either in infancy or early childhood.^{16,17} The manifestation of CLE is usually a progressive severe form of respiratory distress. Frequently, upper respiratory tract infection may be found at the presenting time in the form of wheezing, cough, or recurrent chest infections in elderly children.^{11,18} Intermittent bouts of dyspnea, tachypnea, wheezing, cough and cyanosis are precipitated by feeding, crying or excitement.^{11,12,19} The respiratory symptoms progressively worse, eventually becoming persistent and severe.

Other problems to be considered: Bronchial mucous plug with associated hyper-aeration, extrinsic bronchial compression, agenesis/ hypoagenesis of contralateral lung, bronchial hypoplasia with air trapping peripherally congenital cystic adenomatous malformation, pneumothorax.^{15,20}

Radiological findings are: chest x-ray shows a large hyperlucent lung with attenuated but defined vascularity is observed. Compressed remaining lung on that side, flattened hemi diaphragm, and widened intercostal spaces are also seen. An involved lung is seen herniated across the anterior midline.^{21, 22}

CT thorax can proved detail about the involved lobe and its vascularity, as well as about the remaining lung. CT can show hyperlucent, hyper expanded lobe (attenuated but intact pattern of organized vascularity) with midline sub sternal lobar herniation and compression of remaining lung. Usually the mediastinum is shifted away from the side of abnormal lobe.^{23, 24}

CONCLUSION

Congenital lobar emphysema can present at any age either in the early neonatal period or in infancy. The early diagnosis and importance of

conservative management rather than advocacy of surgery in all cases are noteworthy. The importance of follow-up visits should be stressed as timely conservative management can help avoid surgical intervention.

REFERENCES

1. Canals RJ, Boix OJ, Peiro JL, Ezzeding M, Cobis BN, Linan CS, et al. Congenital lobar emphysema: Report of 38 cases. *Circ Pediatr* 1994; 7:97-101.
2. Fatureto MC, Ferreira DP, Ferraz DA. Congenital lobar emphysema: study of a case. *Rev Port Pneumol* 2008; 14:893-6.
3. Stigers K B, Woodring JH, Kanga JF. The clinical and imaging spectrum of findings in patients with congenital lobar emphysema. *Pediatr Pulmonol* 1991; 14:160-70.
4. Konan Blé R, Coste K, Blanc P. Congenital lobar emphysema: a rare etiology of hyperechoic lung. *Gynecol Obstet Fertil* 2008; 36:529-31.
5. Chao MC, Karamzadeh AM, Ahuja G: Congenital lobar emphysema. *Int J Pediatr Otorhinolaryngol* 2005; 9:549-54.
6. Khemiri M, Ouederni M, Ben Mansour F, Barasaoui S. Bronchogenic cyst: an uncommon cause of congenital lobar emphysema. *Respir Med* 2008; 102:1663-6.
7. Dogan R, Dogan OF, Yilmaz M, Passaglu I, Klipper N, Ozecelik U, et al. Surgical management of Infant with congenital lobar emphysema and concomitant heart disease. *Heart Surg Forum* 2004; 7:644-9.
8. Mei-Zahav M, Konen O, Manson D, Langer JC. Is congenital lobar emphysema a surgical disease? *J Pediatr Surg* 2006; 41:1058-61.
9. Behrman R, Kliegman R. *Nelson Textbook of Pediatrics*. Vol 2, 19th ed. Philadelphia: W.B. Saunders Elsevier; 2010. p. 1742-1803.
10. Paramesh H. *Textbook of Practical Pediatric Pulmonology*. 4th ed. Philadelphia: Mc Grow Hill; 2009. p. 70-9.
11. Lierl M. Congenital abnormalities. In: Hilman B.C, editor. *Pediatric Respiratory Disease: Diagnosis and Treatment*. 1st ed. Philadelphia: W.B. Saunders; 1993. p. 468-72.
12. Krummel TM. Congenital malformation of the lower respiratory tract in: Chernick V, Boat TF, editors. *Kendig's Disorders of the Respiratory Tract in Children*. 6th ed. Philadelphia: W.B. Saunders; 1998; p. 310-1.
13. Lincoln JC, Stark J, Subramanian S, Aberdeen E, Bonham-Carter RE, Berry CL, et al. Congenital lobar emphysema. *Ann Surg* 1971; 173:55-62.
14. Carrol ED, Campbell ME, Shaw BN, Pilling DW. Congenital lobar emphysema in congenital cytomegalovirus infection. *Pediatr Radiol* 1996; 26: 900-2.
15. Martin R, Fanaroff A, Walsh M. *Fanaroff and Martin's Neonatal-Perinatal Medicine*. 9th ed. 2008: 1002- 3.
16. Dewan RK, Kesieme EB, Sisodia A, Ramchandani R, Kesieme CN. Congenital malformation of lung parenchyma: 15 years' experience in a thoracic surgical unit. *Indian J Chest Dis Allied Sci* 2012; 54:105-9.
17. Toyoshima M, Suda T, Chida K. Asymptomatic congenital lobar emphysema in a young adult. *Intern Med* 2012; 51:2839-40.
18. Lincoln JC, Stark J, Subramanian S, Aberdeen E, Bonham-Carter RE, Berry CL, et al. Congenital lobar emphysema. *Ann Surg* 1971; 173: 55-62
19. Man DW, Hamdy MH, Hendry GM, Bissett WH, Forfar JO. Congenital lobar emphysema: problems in diagnosis and management. *Arch Dis Child* 1983; 58:709-12.
20. Ben Abdallah R, Bouthour H, Hella Y, Ben Malek MR, Gharbi Y, Kaabar N. Congenital pulmonary malformations: clinical, radiological and treatment features. *Tunis Med* 2013;91:66-9
21. Nath MP, Gupta S, Kumar A, Chakrabarty A. Congenital lobar emphysema in neonates: Anaesthetic challenges. *Indian J Anaesth* 2011; 55:280-3.
22. Shanti CM, Klein MD. Cystic lung disease *Semin Pediatr Surg* 2008; 17:2-8.
23. Chia CC, Huang SC, Liu MC, Se TY. Fetal congenital lobar emphysema. *Taiwan J Obstet Gynecol* 2007; 46:73-6.
24. Ang L, He XL, Zhang ZX. Congenital lobar emphysema complicated with right upper lung bronchial dysplasia in a case. *Zhonghua Er Ke Za Zhi* 2006; 44:956.

CONFLICT OF INTEREST
 Authors declare no conflict of interest.
GRANT SUPPORT AND FINANCIAL DISCLOSURE
 None declared.