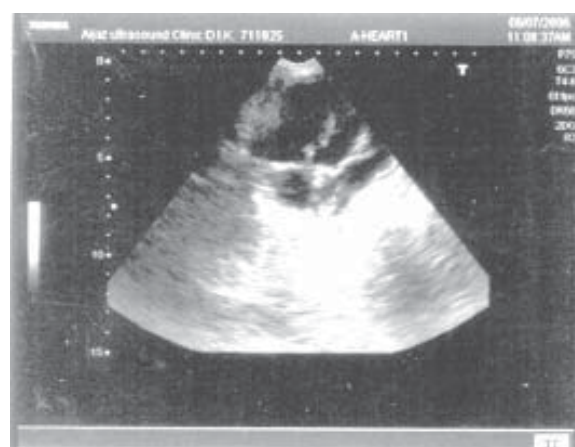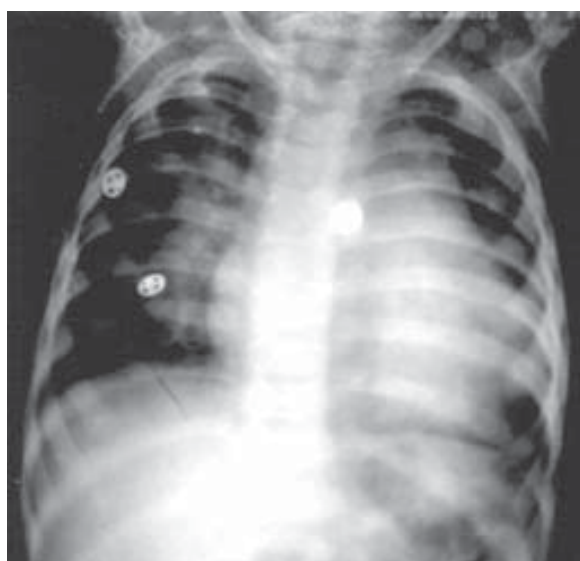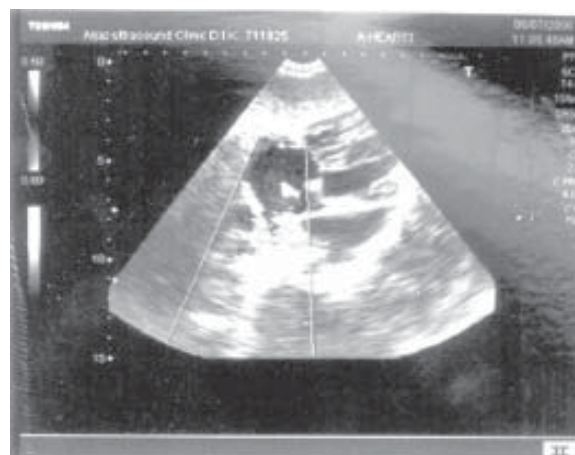

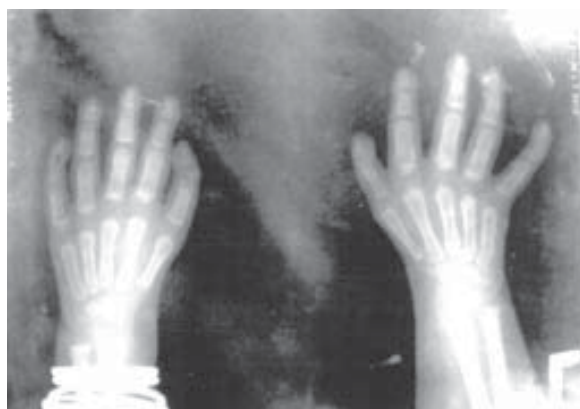IMAGES IN CLINICAL MEDICINE



HOLT-ORAM SYNDROME

It is an autosomal dominant condition, consisting of atrial &/or ventricular septal defect and thumb anomalies (absent /hypoplastic /triphalangeal).

This young girl of one year age, presented with fever, cough and growth retardation. She had hypoplastic thumbs and a loud pansystolic murmur down the left sternal border. Chest x-ray showed cardiomegaly and echocardiography confirmed a big peri-membranous VSD: a case of Holt-Oram syndrome.

Fazal-ur-Rahman Khan
Associate Prof. Paediatrics
Gomal Medical College
D.I. Khan, Pakistan