

# KARTAGENER'S SYNDROME

Ihsan-ullah Mahsud and Shahab-ud Din

Department of Medicine, Gomal Medical College, D.I. Khan, Pakistan

## ABSTRACT

Lower respiratory tract infections are a common problem in our society. In recurrent lower respiratory tract infections the cause may be either general impairment of immune mechanism, abnormalities of mucus or abnormalities of cilia. We report a case where the patient was having recurrent lower and upper respiratory tract infections and had situs inversus totalis. The present case i.e. Kartagener's syndrome is an inherited disorder transmitted in autosomal recessive manner with variable penetrance. Although there is no specific treatment for this condition, failure to recognize the condition may subject the patient to unnecessary repeated admissions and investigations and inappropriate treatment.

**Key words:** Kartagener's syndrome, Dextrocardia, Situs inversus, Bronchiectasis, Sinusitis.

## INTRODUCTION

Kartagener Syndrome's (KS) is an autosomal recessive disorder<sup>1</sup> characterized by dextrocardia, bronchiectasis and sinusitis<sup>2</sup>. The condition was described for the first time by Siewert in 1904, therefore some people call it siewert syndrome but the details of the condition were given by Manes Kartagener in 1933 and it is commonly known as Kartagener's syndrome. Basic problem is defective movement of the Cilia. Males are generally infertile because of immotile sperms,<sup>3,4</sup> however some males have completely normal spermatozoa<sup>5,6</sup> and cases of semi-sterility in females have been reported.<sup>4,7</sup> Patients with Kartagener syndrome may also have anosmia.<sup>8</sup>

## CASE HISTORY

An 18 years old male patient presented with productive cough, rhinorrhoea, and headaches since childhood with episodic fever and worsening of symptoms. His previous record showed a lot of investigations including investigations for tuberculosis such as repeated chest x-rays and examination of the sputum. His record also revealed that he received several courses of antibiotics, antihistamines, bronchodilators, inhaled and oral corticosteroids, and even anti-tuberculous drugs but the response was only partial and temporary. Considering his ill health, duration of symptoms and uncertainty about the cause of the disease he was admitted to Medical Ward in DHQ Teaching Hospital, D.I. Khan. On examination he was febrile with nasal discharge, wheezy chest and bilateral coarse crackles. His heart sounds were heard best on the right side of the chest. There was no digital clubbing. Initial suspicion was that of bronchial asthma

with recurrent chest infections and the possibility of cystic fibrosis was also kept in mind. However, chest x-ray showed not only bronchiectasis especially in the lower zones but also dextrocardia. (Figure- 1)

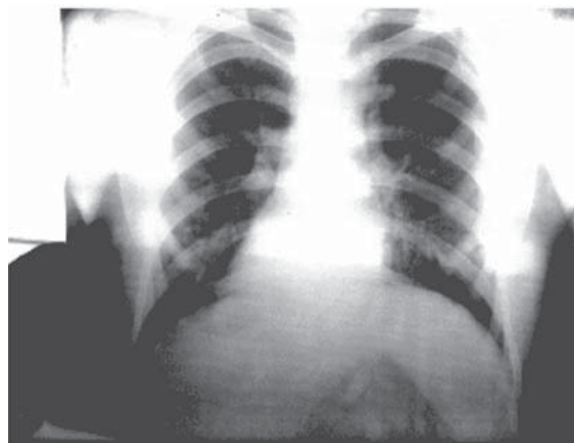


Fig-1: Chest x-ray (PA view) showing dextrocardia.

Ultrasound of the abdomen showed spleen on the right side of the abdomen while liver on the left. (Figure-2)

ECG showed QS waves and inverted T waves in Lead-I along with other features of dextrocardia. (Figure-3)

Sinus radiographs showed mucosal thickening, opacified sinus cavities and other features of chronic sinusitis. The case was discussed with radiologist and otorhinolaryngologist. Spirometry revealed an obstructive ventilatory defect. Other

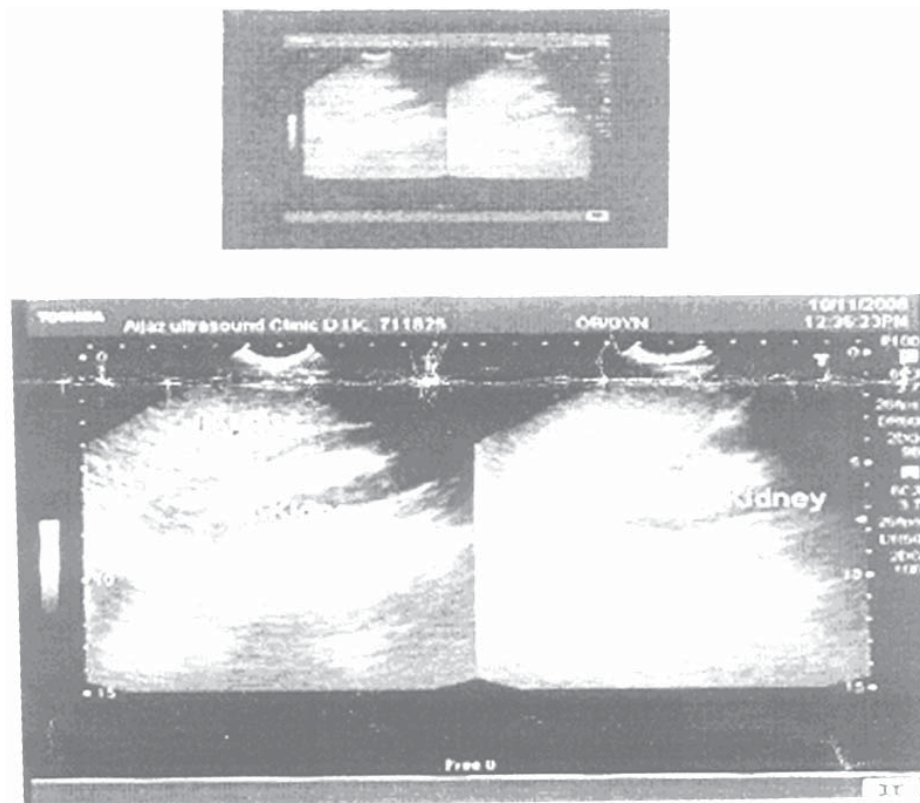


Fig-2: Ultrasonography of the abdomen showing situs inversus.

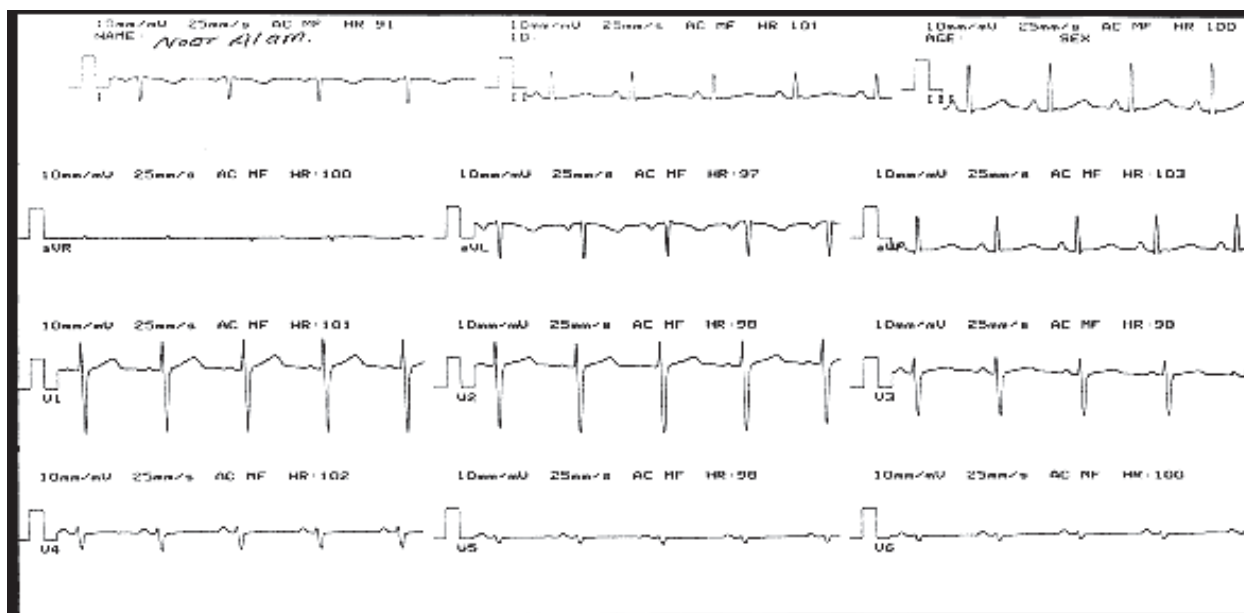


Fig-3: ECG showing typical changes of dextrocardia.

routine and relevant investigations were performed except semen analysis for sperm motility because the patient was unmarried and declined to do so. Considering the clinical picture of the patient, sinusitis, bronchiectasis and situs inversus,

the clinical diagnosis of Kartagener's syndrome was made. The condition was explained to the patient and he was treated with antibiotics, antipyretics, mucolytics and inhaled bronchodilators.

---

## DISCUSSION

Kartagener's syndrome is a rare disorder. Sinusitis, bronchiectasis, situs inversus and male infertility occurring in this condition are attributed to abnormal ciliary motility. Cilia may be immotile or may show uncoordinated and inefficient movement patterns. Ciliary movement disorders may be congenital or acquired. Congenital ciliary disorders are labeled as primary ciliary dyskinesias (PCDs). Approximately one half of the patients with PCD have situs inversus. Those patients having PCD with situs inversus are known as Kartagener's syndrome.<sup>9</sup>

It has been proposed that normal ciliary beating is necessary for visceral rotation during embryonic development. In patients with PCD half of the patients will have situs inversus i.e. will be cases of KS and the other half normal situs because of random rotation.<sup>10</sup> Abnormal ciliary motility results in general impairment of respiratory defense mechanisms due to problem with bacterial clearance leading to recurrent upper and lower respiratory tract infections. In abnormalities of cilia, structural abnormalities of dynein arms are the most common,<sup>11</sup> although abnormalities of the radial spokes and microtubules can also account for the condition. In rare cases no structural ciliary abnormality is detectable even though ciliary function is abnormal and the clinical syndrome is typical.<sup>12,13</sup> Patients with Kartagener's syndrome may have either situs solitus i.e dextrocardia only or situs inversus totalis where all the viscera are on the opposite side,<sup>10</sup> including left sided appendix.<sup>5</sup> The patient in this case was having situs inversus totalis. Demonstration of abnormal ciliary movement needs electron microscopic studies of biopsies obtained from the nasal mucosa or trachea. However these procedures are invasive and available only at specialized centers, therefore the diagnosis of Kartagener's syndrome in this case was clinical, supported by imaging studies.

The condition should be kept in mind in a patient presenting with;

1. Recurrent sinusitis and bronchiectasis.
2. Asthma like symptoms and signs responding poorly to conventional treatment.
3. Recurrent lower respiratory tract infections causing fever, sweating and weight loss, tempting the physician to give a trial of anti-tuberculous drugs.

From the preceding discussion it is also clear that those patients of Kartagener's syndrome hav-

ing situs inversus totalis will present with left sided appendicitis if they develop this problem at some stage in their lives.

## REFERENCES

1. Gorham GW, Merselis JG Jr. Kartagener's triad: a family study. *Bull Johns Hopkins Hosp*; 1959; 104: 11-16.
2. Kartagener M, Horlacher A. Situs viscerum inversus and polyposis nasi in einem Falle familiaerer Bronchiectasien. *Beitr Klin Tub* 1936; 87: 331-33.
3. Guerrant JL, Douty T, Tegtmeier C, Jahrsdoerfer RA. Bronchiectasis in the immotile cilia syndrome. *New Eng J Med* 1978; 298: 282.
4. Afzelius BA. Personal communication Stockholm, Sweden 1976.
5. Jonsson MS, McCormick JR, Gillies CG, Gondo B, Kartagener syndrome with motile spermatozoa, *New Eng J Med* 1982; 307: 1131-33.
6. Sameul I. Kartegener syndrome with normal spermatozoa. *JAMA* 1987; 258: 1329-30.
7. Arge E. Transposition of the viscera and sterility in men. *Lancet* 1960; 1: 412-14.
8. Goldstein JL. Personal communication Dallas, Texas, 1/25/1979.
9. Olbrich H, Haffnax K, Kispert A, Volkel A, Volz A, Sasmaz G, et al. Mutation in DNA H5 cause primary ciliary dyskinesia and randomization of left-right asymmetry. *Nature Genet* 2002; 30: 143-44.
10. None PG, Bali D, Carson JL, Sannuti A, Gipson CL, Ostrowski LE, et al. Discordant organ laterality in monozygotic twins with primary ciliary dyskinesia. *Am J Med Genet* 1999; 82: 155-60.
11. Eavey RD, Nadol J B Jr, Holmas LB, Laird NM, Lapey A, Joseph MP, et al. Kartagener's syndrome: A blinded controlled study of cilia ultrastructure. *Arch Otolaryng Head Neck Surg* 1986; 112: 646-50.
12. Herzon F, Murphy S. Normal ciliary ultrastructure in children with Kartagener's syndrome. *Ann Otol Rhinol Laryng* 1980; 89: 81-83.
13. Schidlow DV, Katz SM. Immotile Cilia syndrome. *New Eng J Med* 1983; 308: 595.

### Address for Correspondence:

Dr. Ihsan-ullah Mahsud  
Associate Professor Medicine  
Gomal Medical College  
D.I. Khan  
Cell: 03005792078